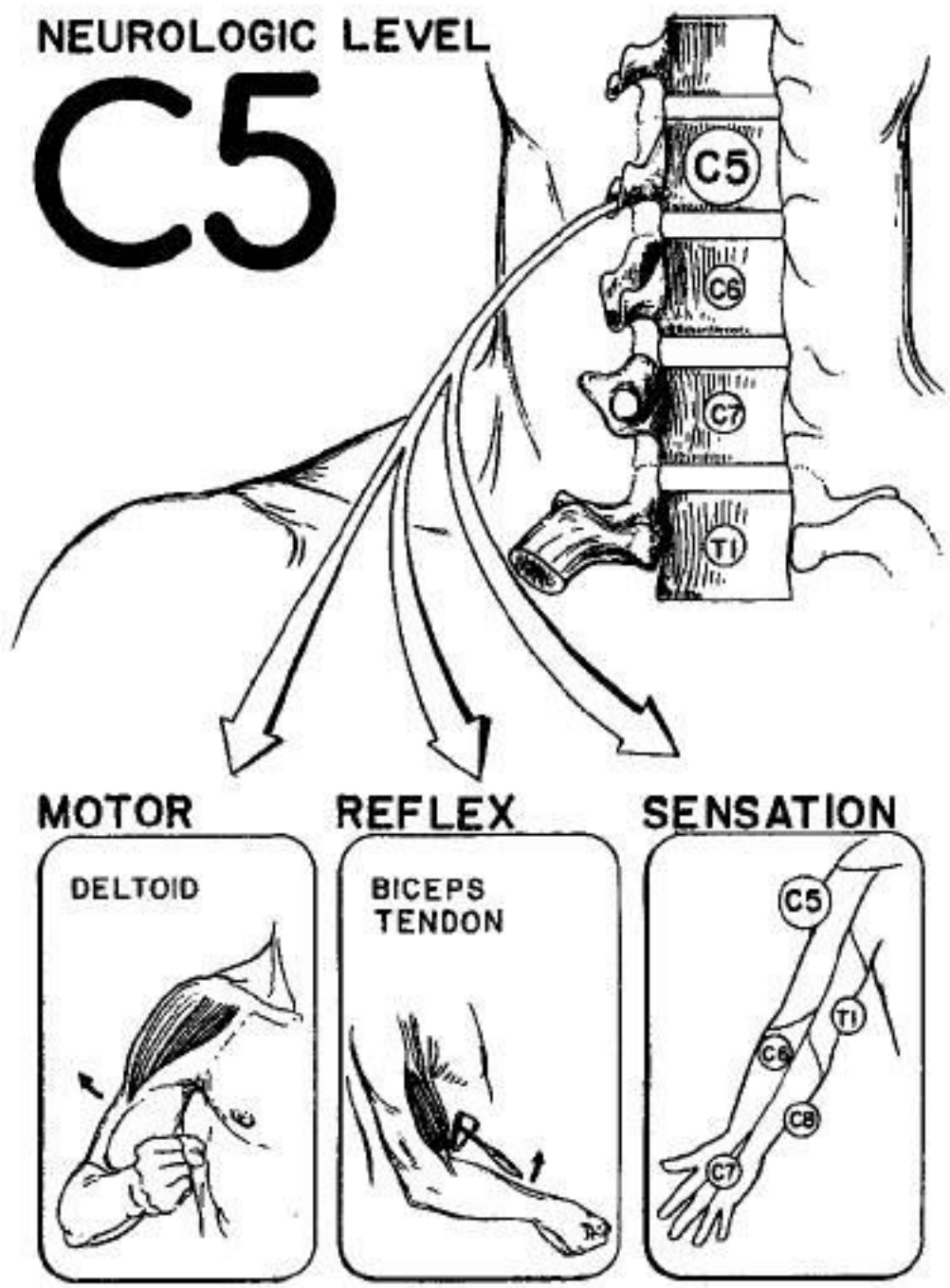

FIG. 1–2. Neurologic level C5.

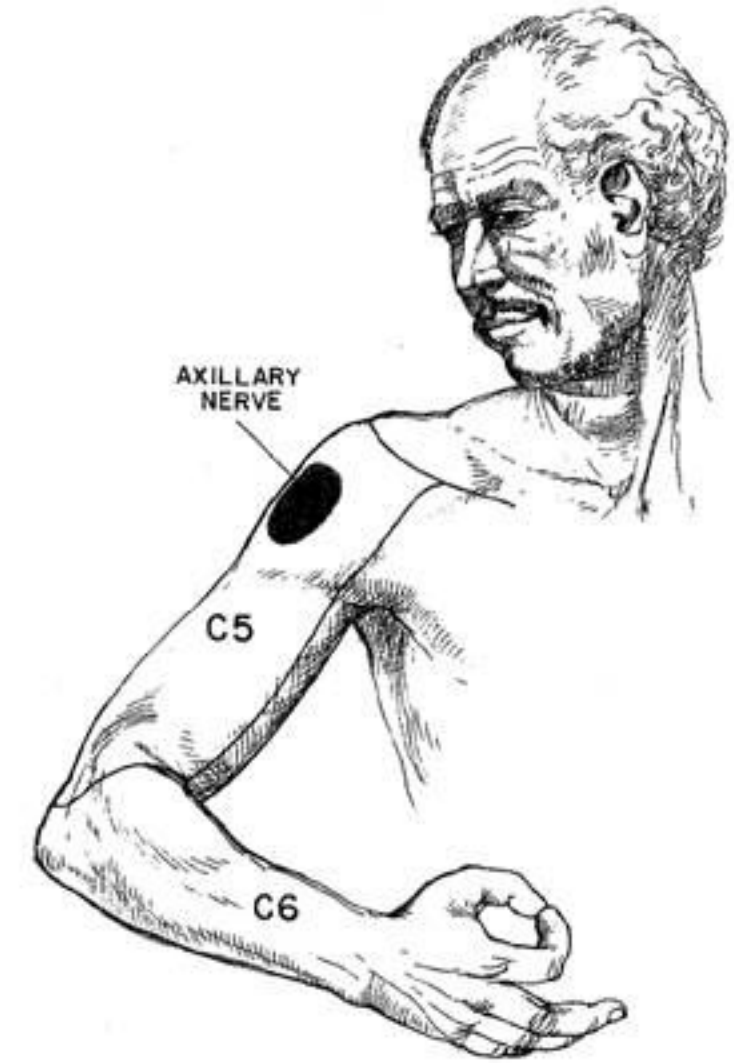

FIG. 1–9. The sensory distribution of the C5 neurologic level.

Shoulder Abduction

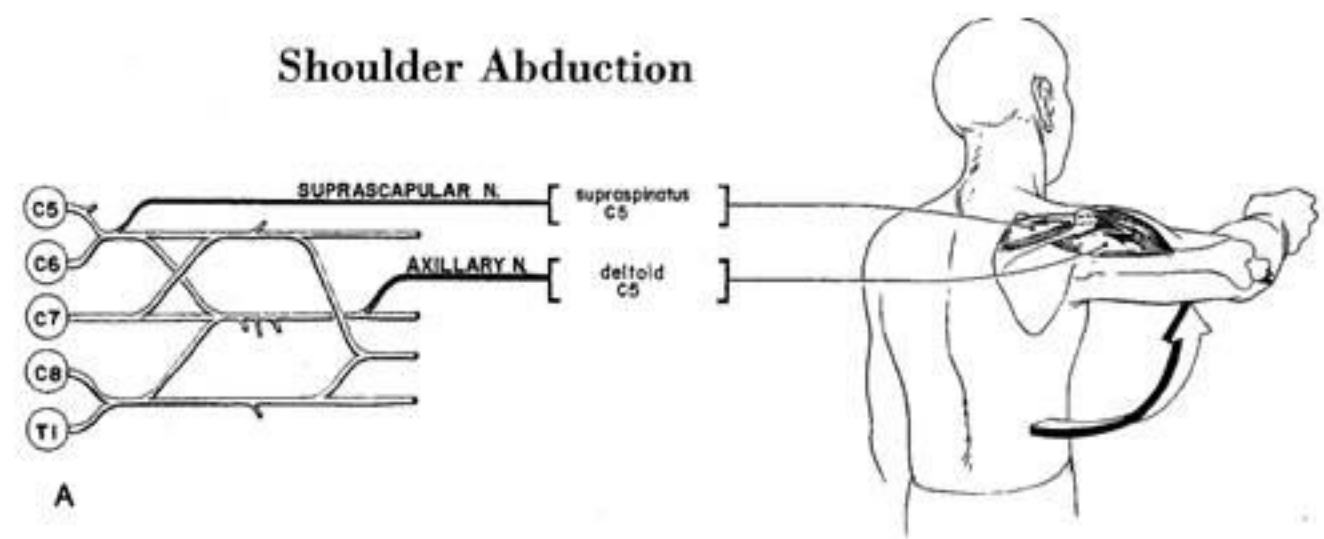

FIG. 1–3A.

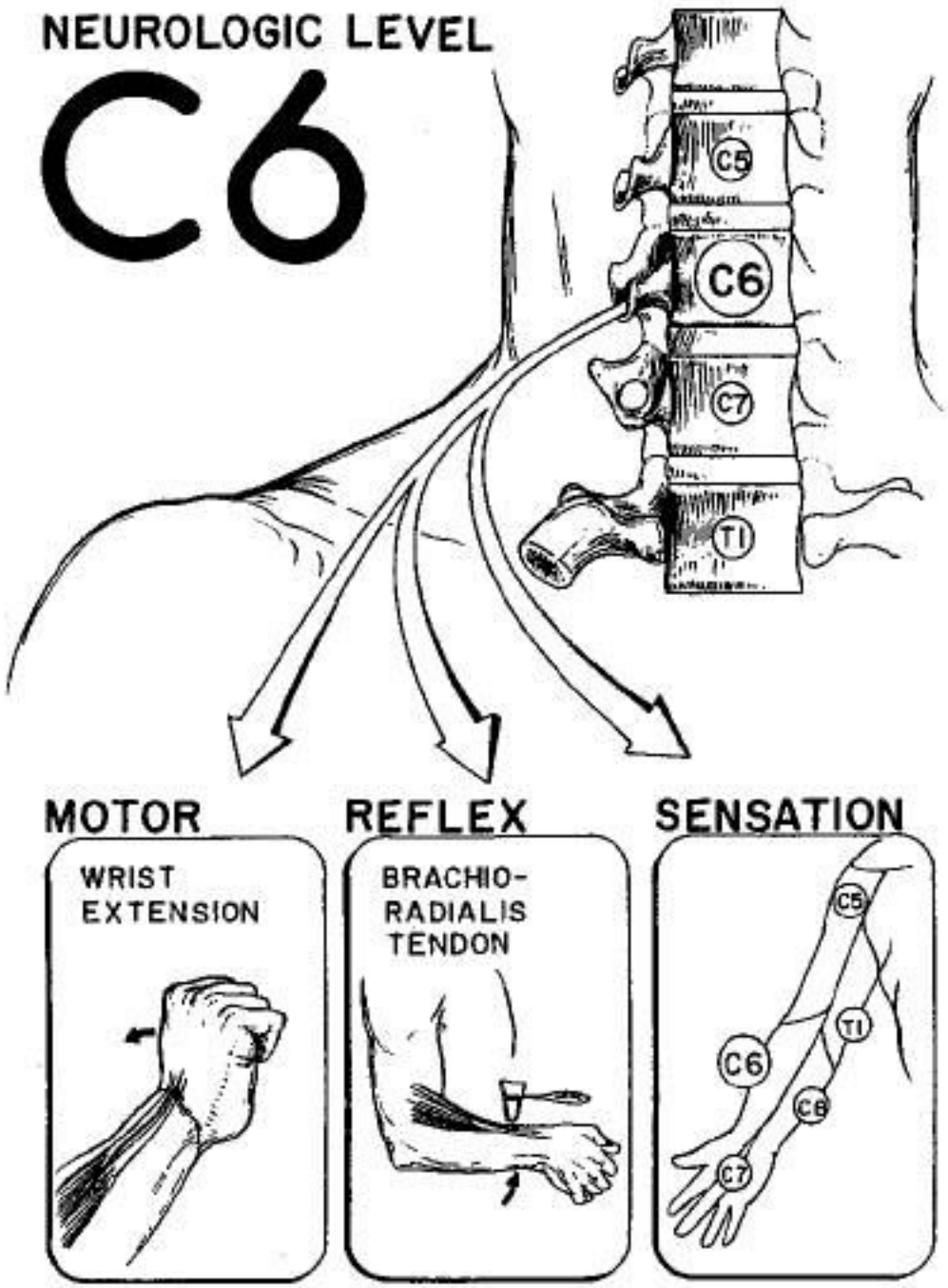

FIG. 1–10. Neurologic level C6.

FIG. 1–14. An easy way to remember the sensory distribution of C6.

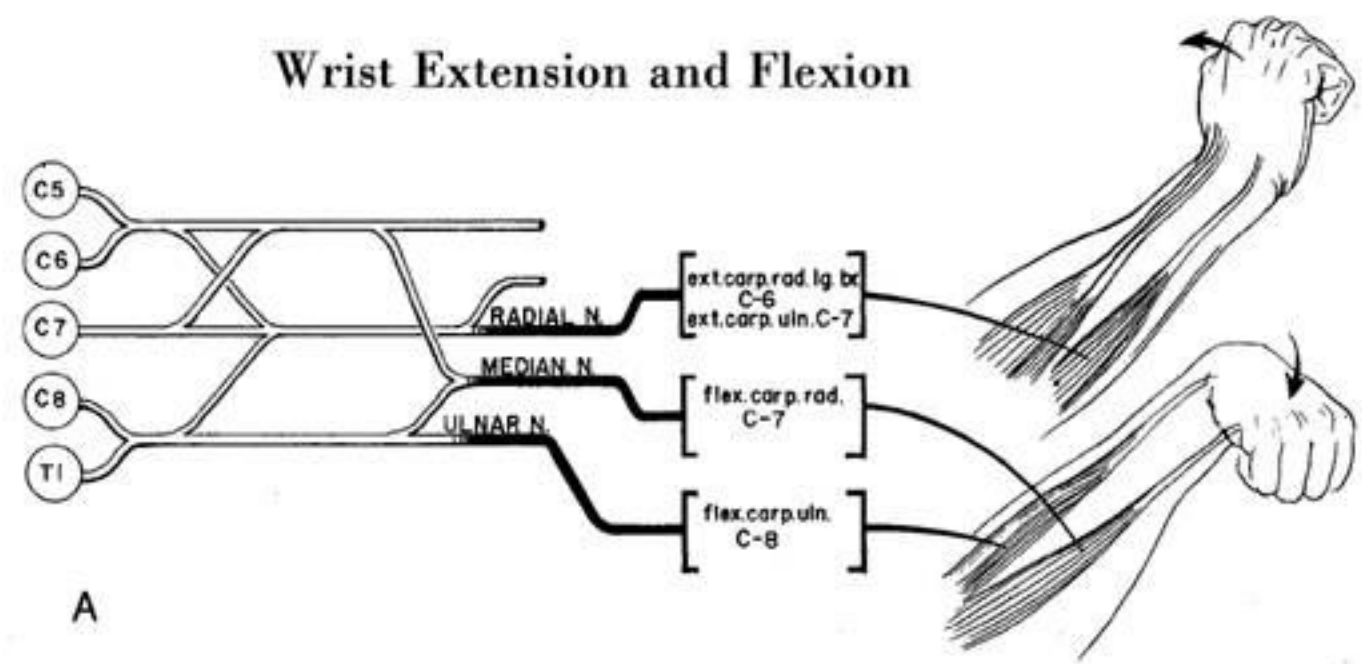

FIG. 1–11A.

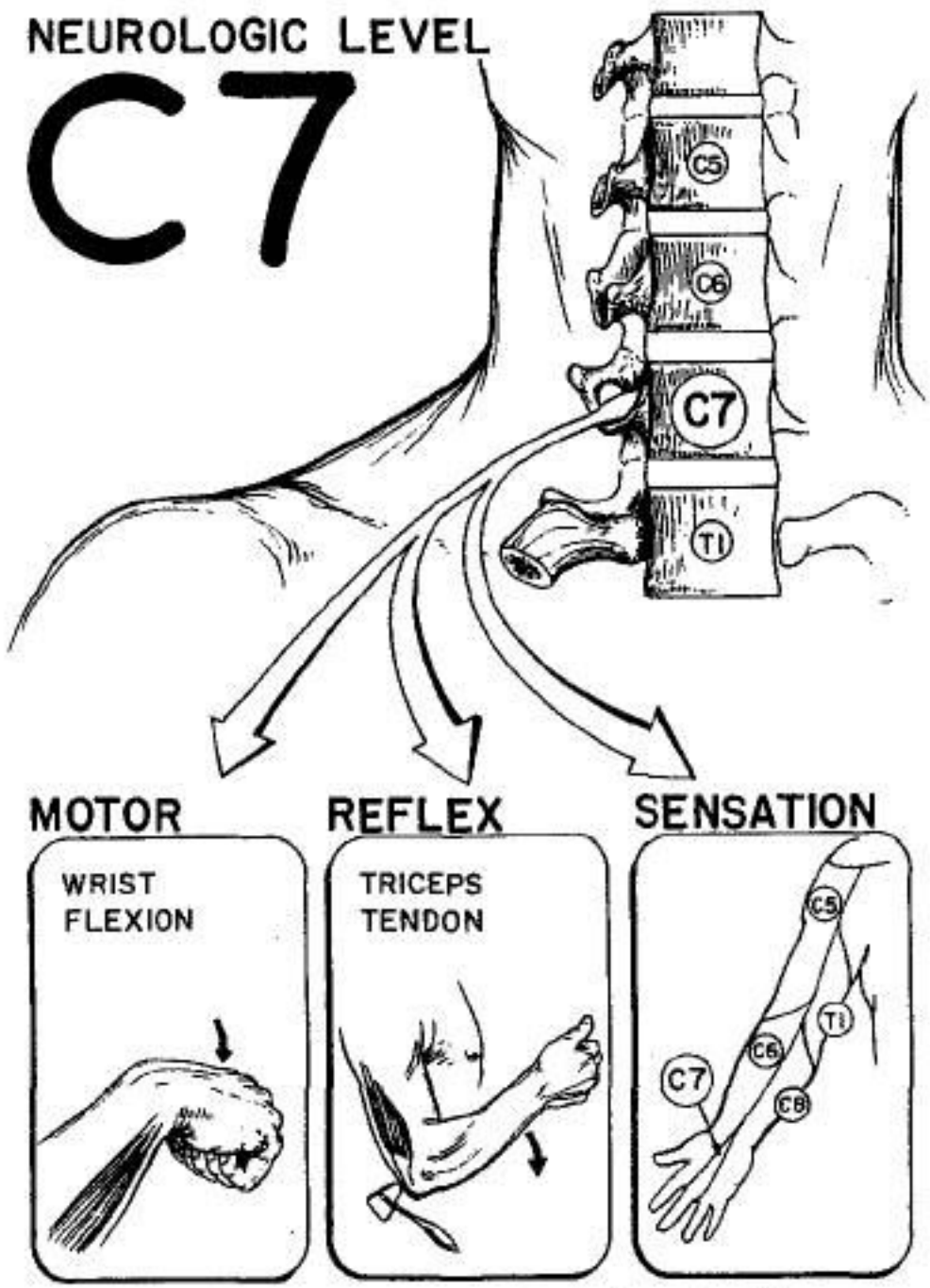

FIG. 1–15. Neurologic level C7.

Sensation Testing

MIDDLE FINGER. C7 supplies sensation to the middle finger. Since middle finger sensation is also occasionally supplied by C6 and C8, there is no conclusive way to test C7 sensation.

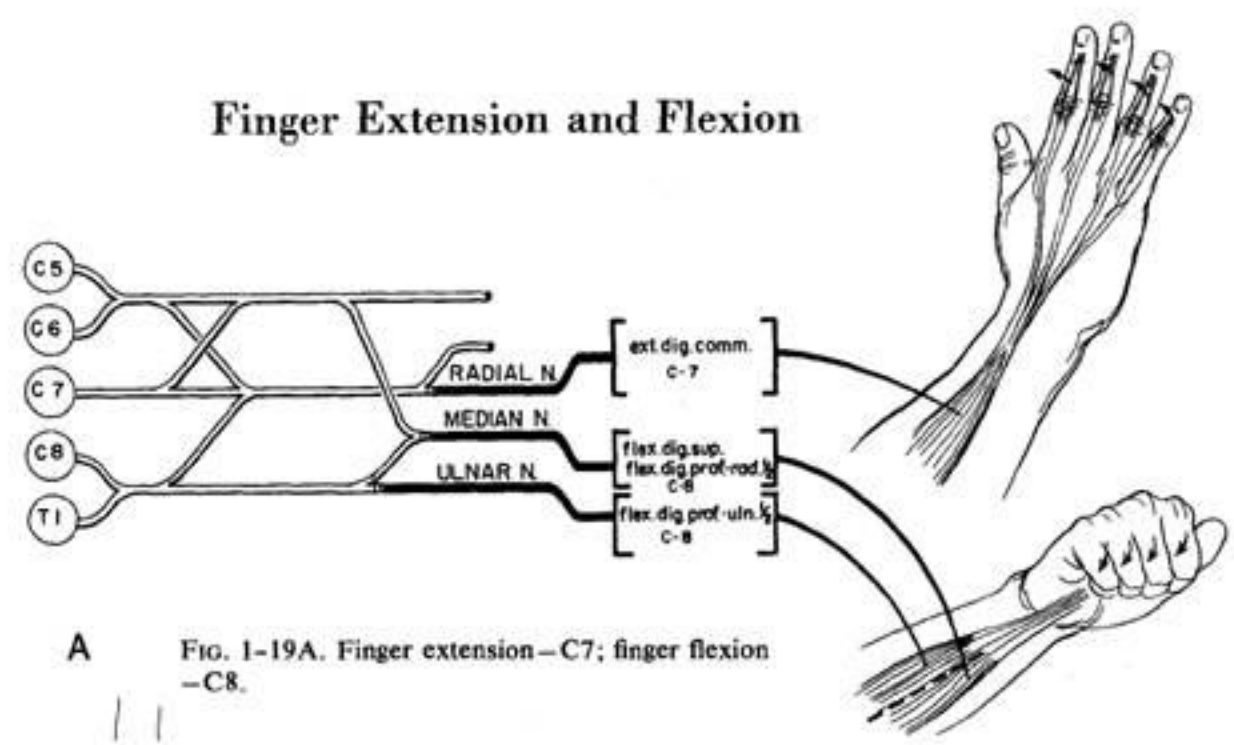

A FIG. 1-19A. Finger extension—C7; finger flexion—C8.

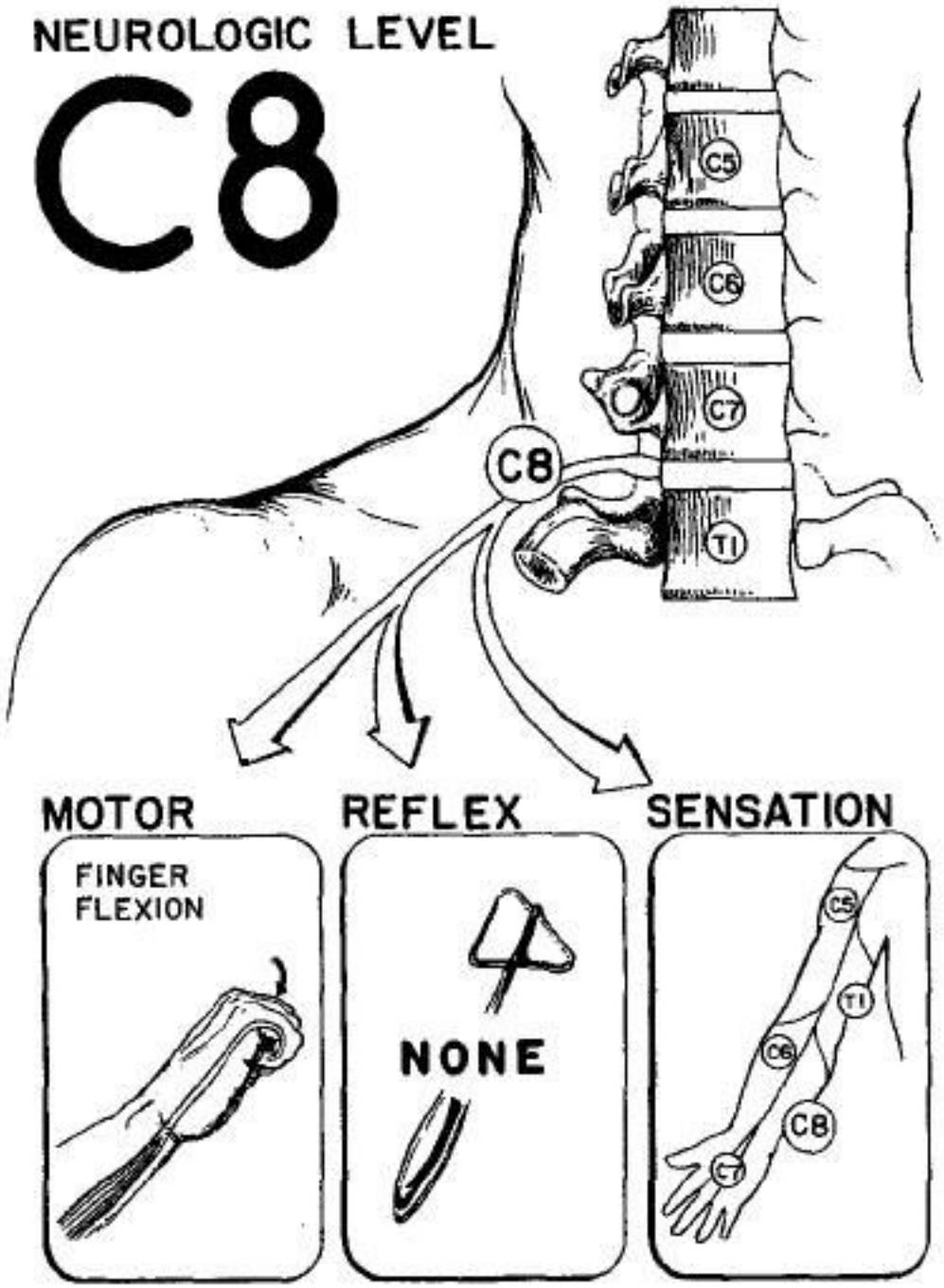

FIG. 1–22. Neurologic level C8.

FIG. 1–24. An easy way to remember that C8 innervates the finger flexors.

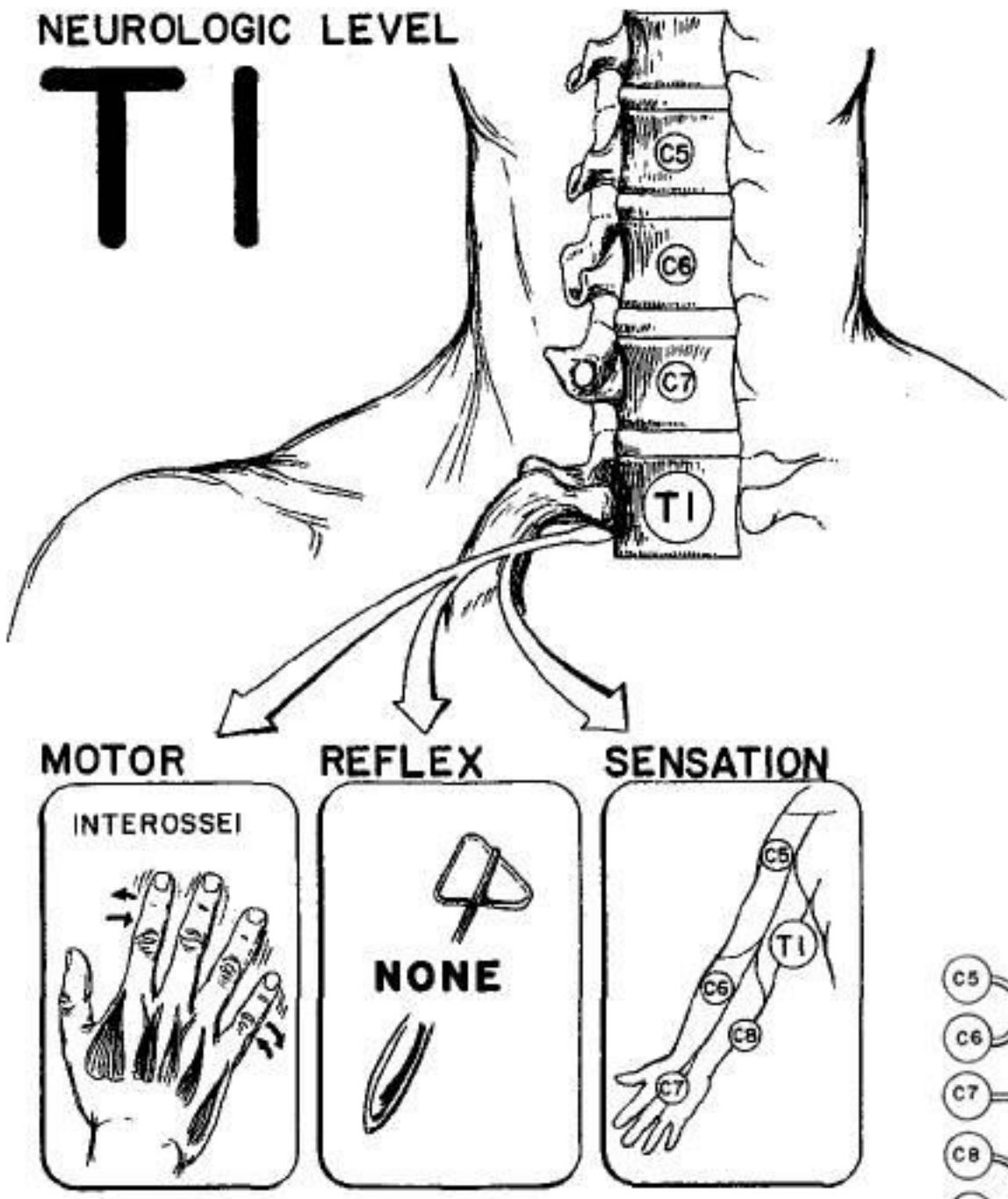

FIG. 1-25. Neurologic level T1.

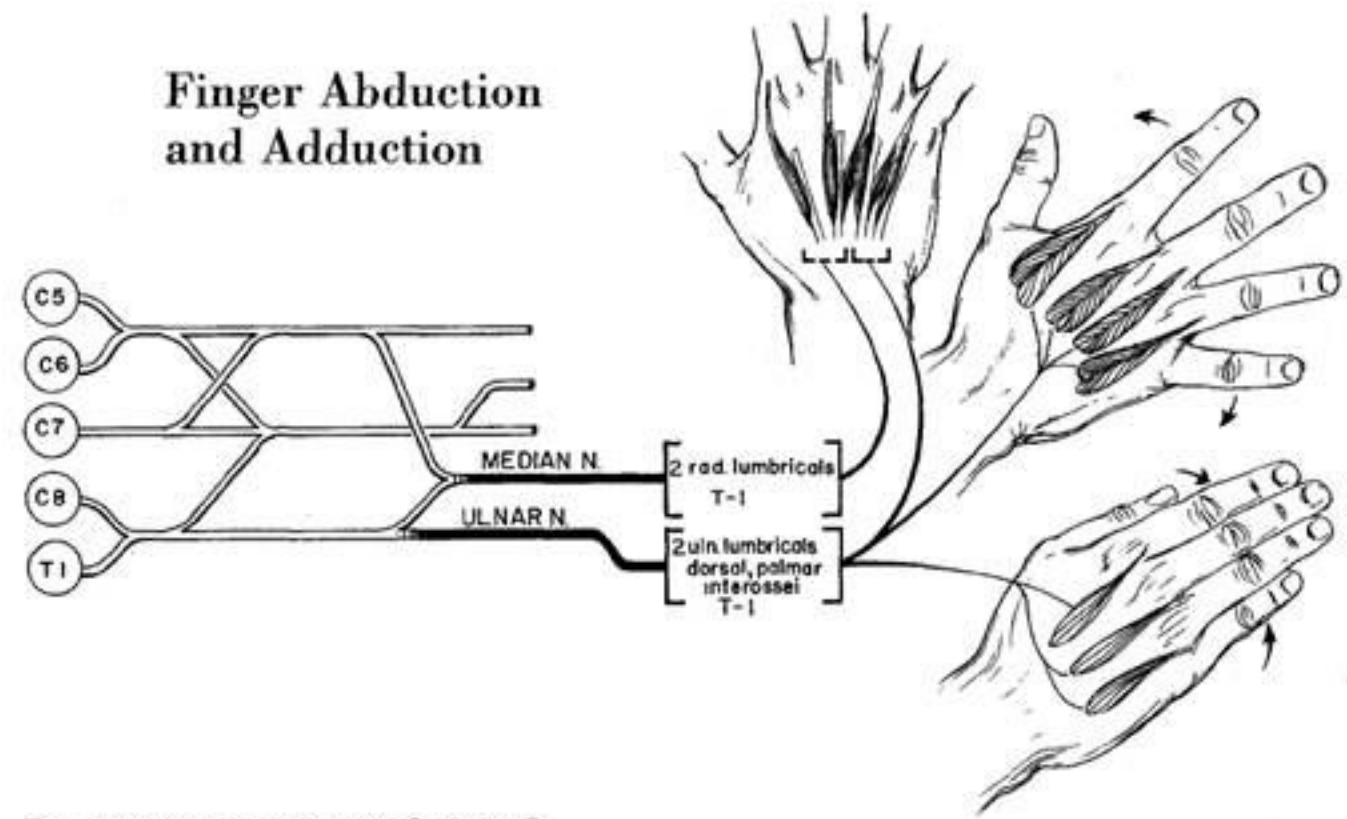

FIG. 1-26 (See opposite page for legend)

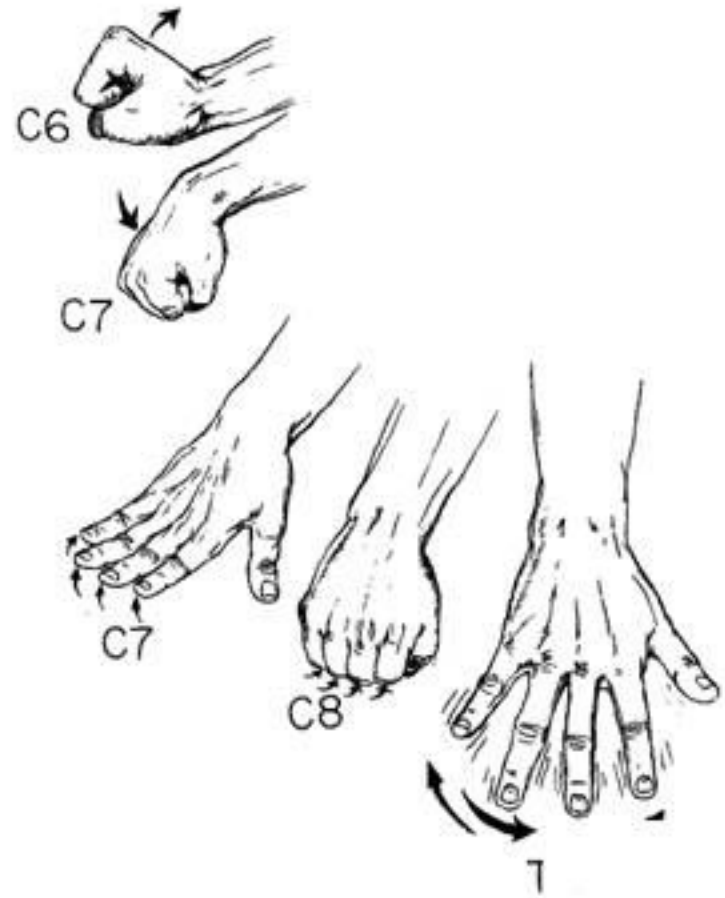

FIG. 1–29. Summary of muscle testing extremity.

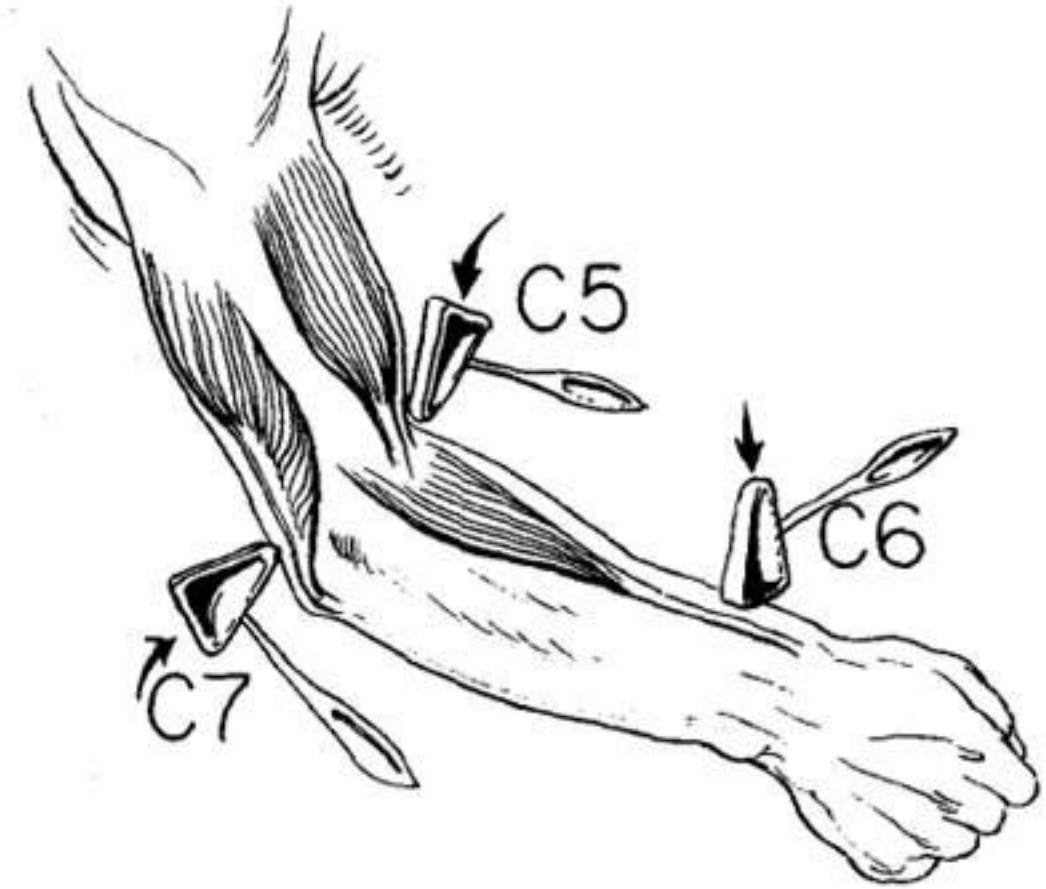

ing for the upper

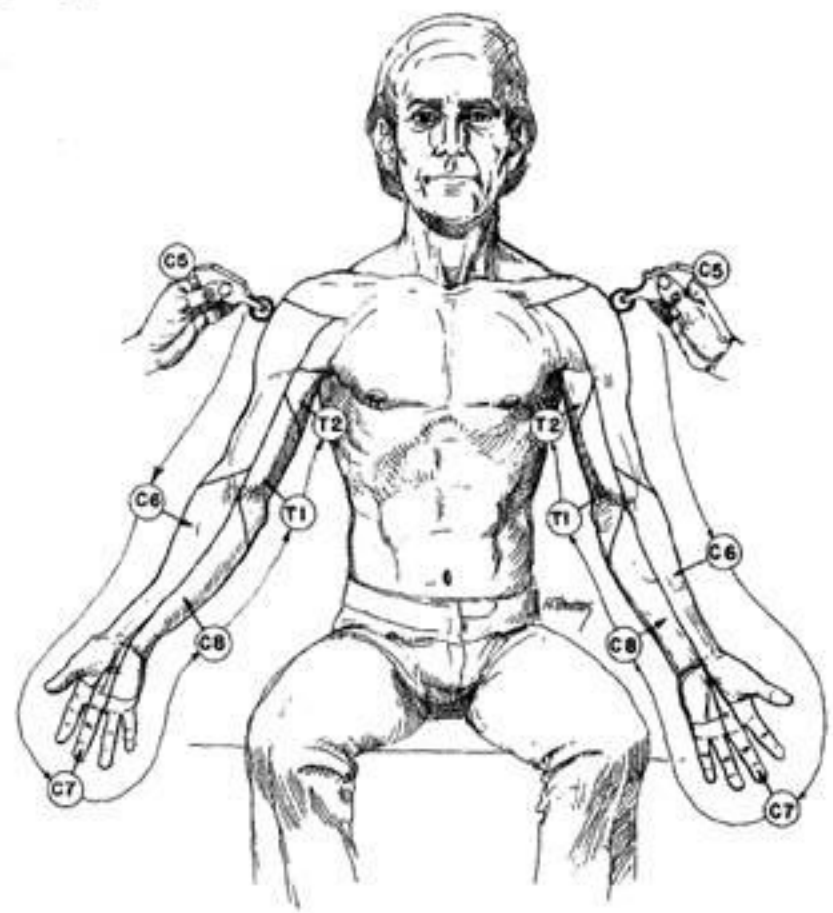

FIG. 1–31. Summary of sensation for the upper extremity.

TESTING OF INDIVIDUAL NERVE ROOTS, T2 TO S4

Neurologic Levels T2 to T12

Muscle Testing

INTERCOSTALS. The intercostal muscles are segmentally innervated and are difficult to evaluate individually.

RECTUS ABDOMINUS. The rectus abdominus muscles are segmentally innervated by the primary anterior divisions of T5 to T12 (L1), with the umbilicus the dividing point between T10 and T11.

FIG. 2–1. Beevor's sign.

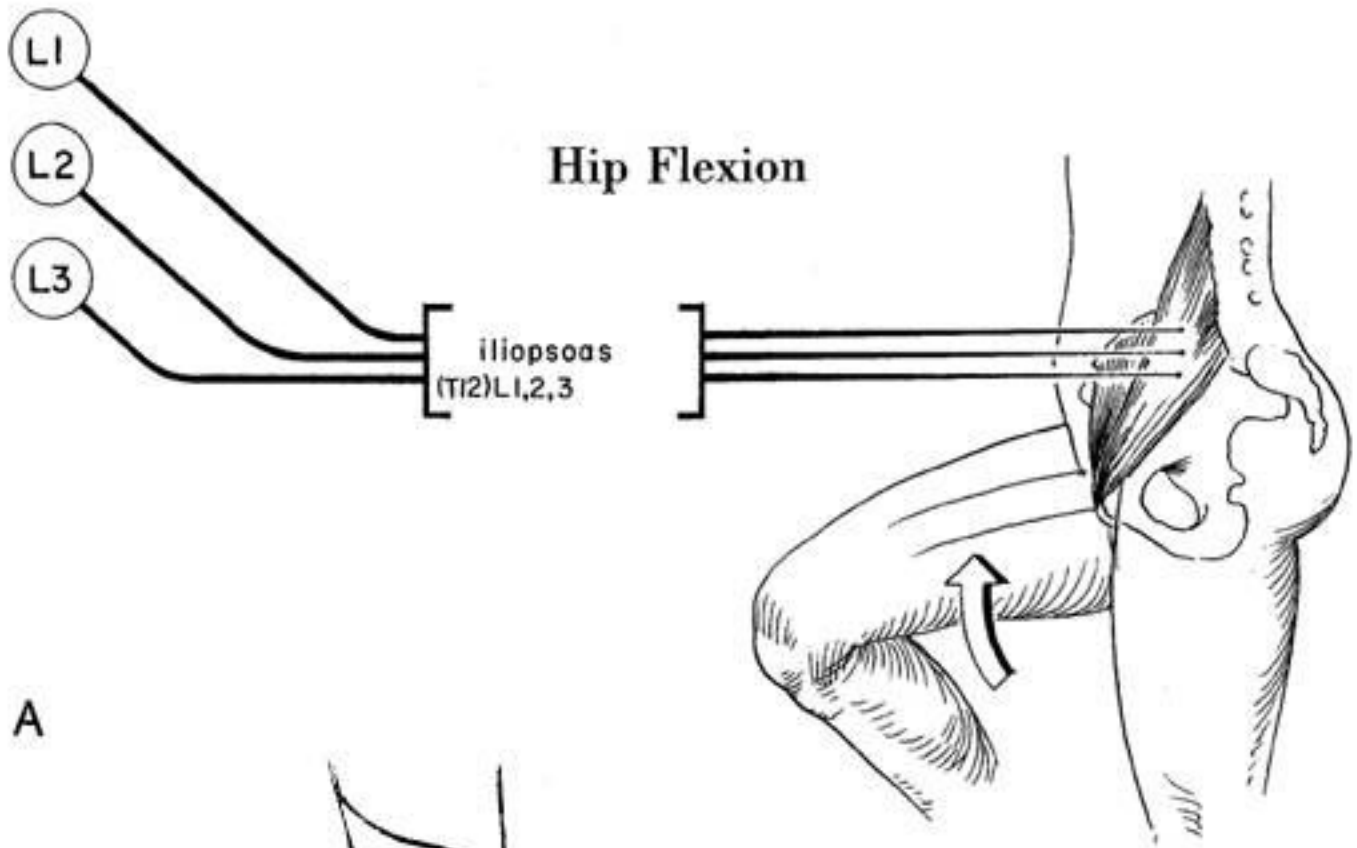

A

FIG. 2-2A. (T12), L1, 2, 3 – Hip flexion.

Fig. 6–49. Prueba muscular de flexión para el músculo psoasiliaco.

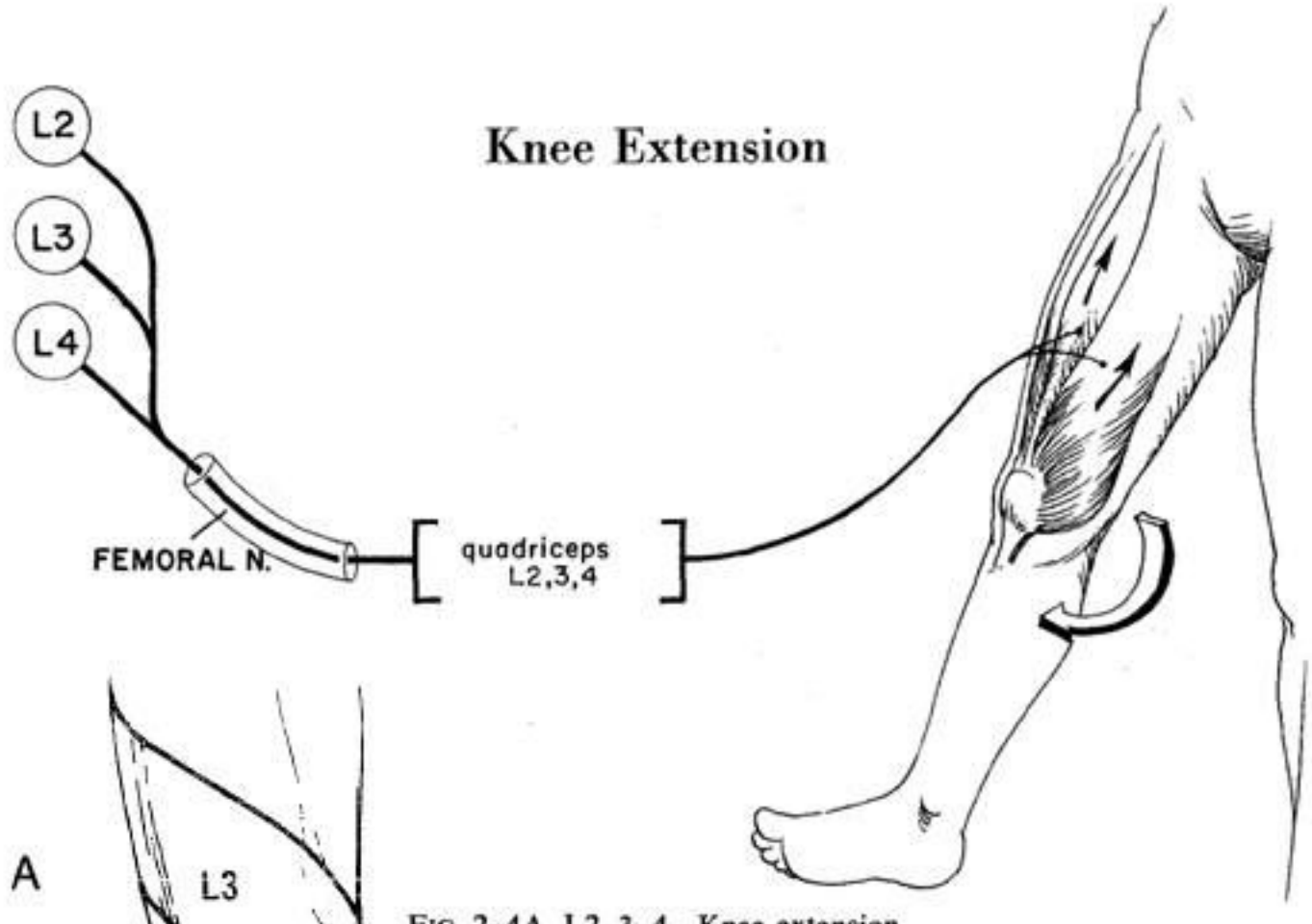

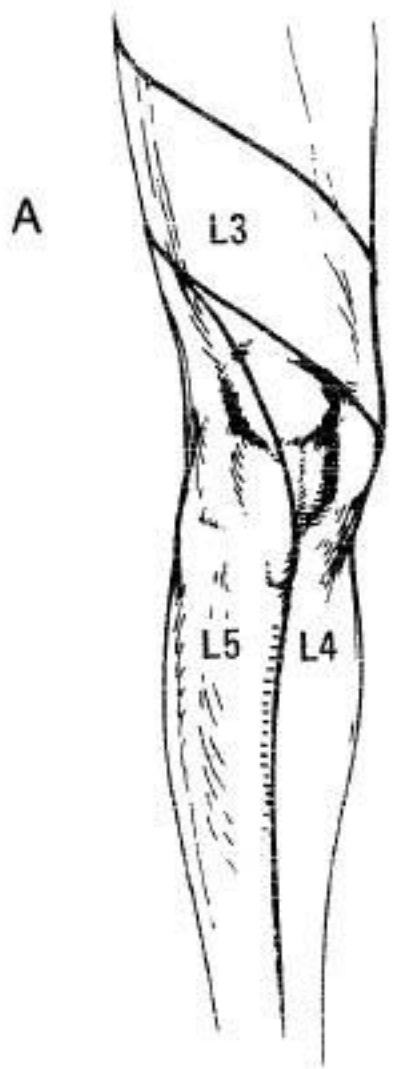

FIG. 2-4A. L2, 3, 4 – Knee extension.

Fig. 7–53. Prueba del músculo cuadríceps.

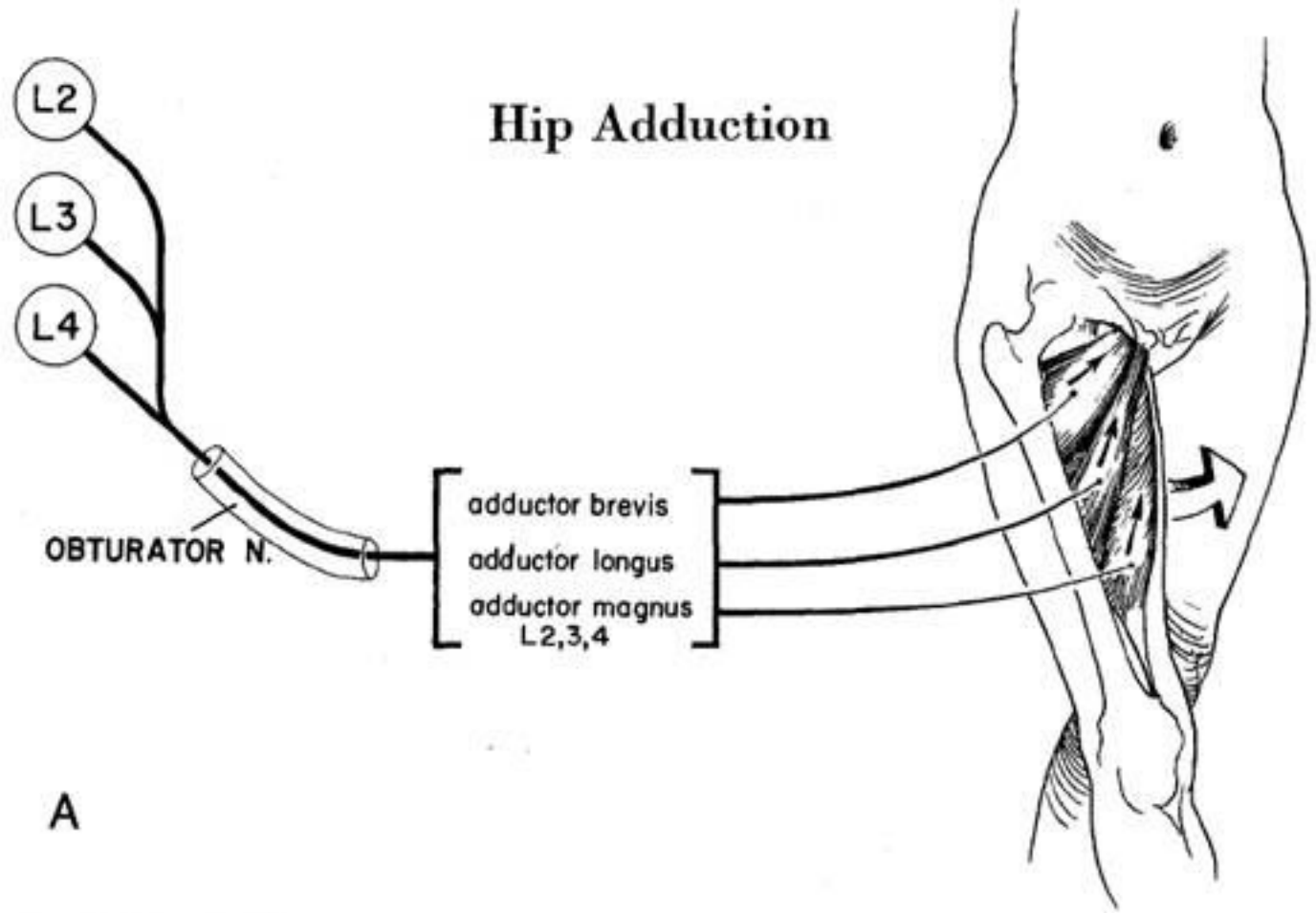

. L2, 3, 4 – Hip adduction.

Fig. 6–53. Prueba de la potencia de los músculos aductores.

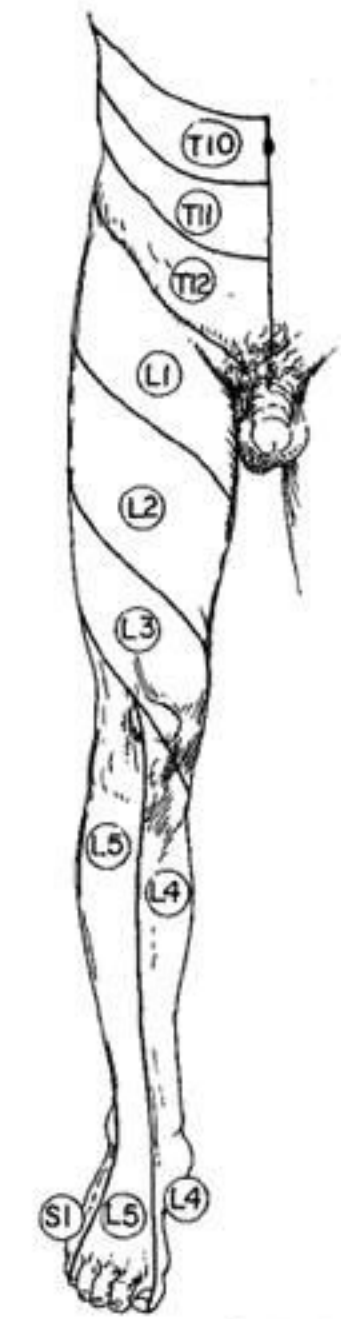

FIG. 2–9. Dermatomes of the lower extremity.

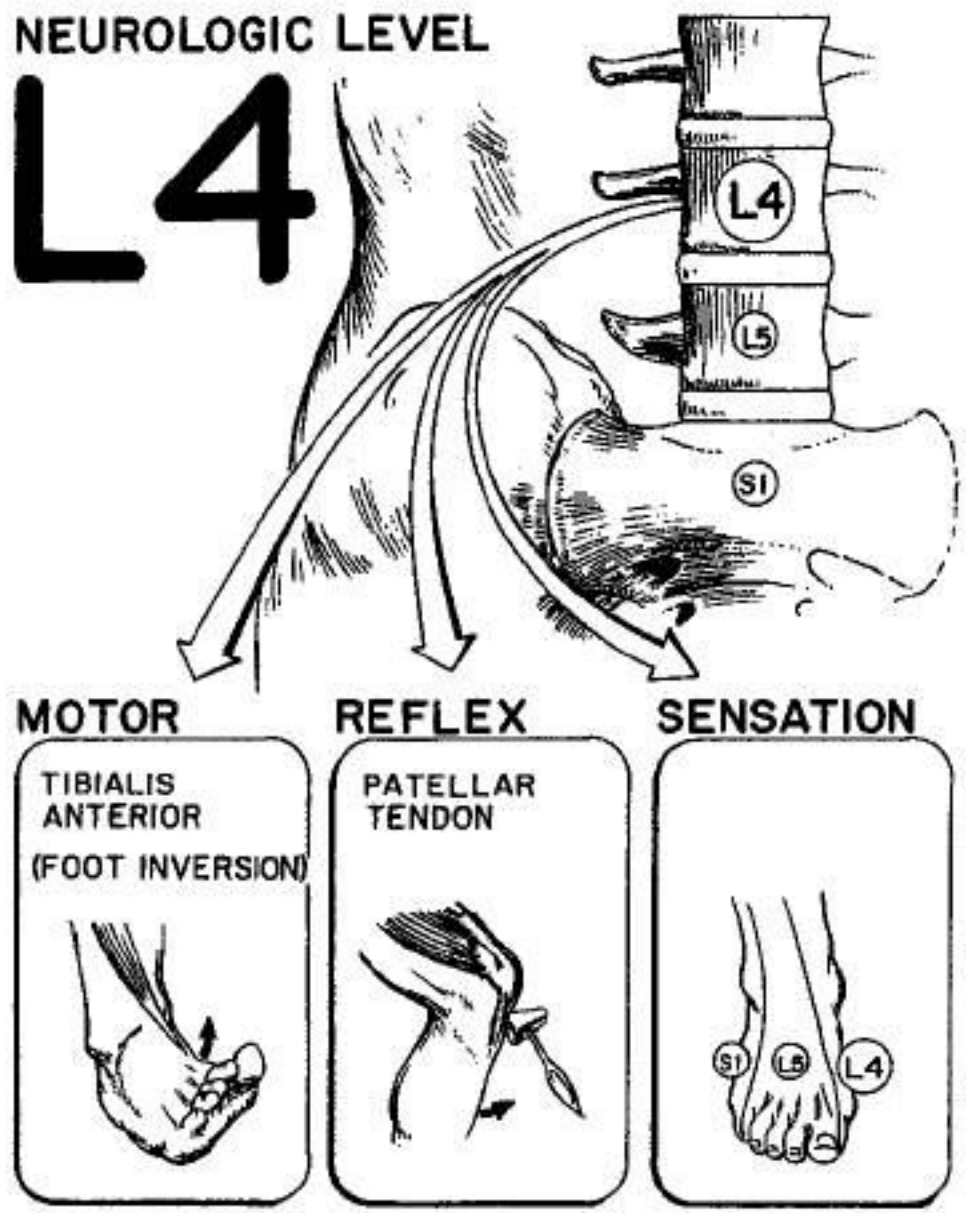

FIG. 2–10. Neurologic level L4.

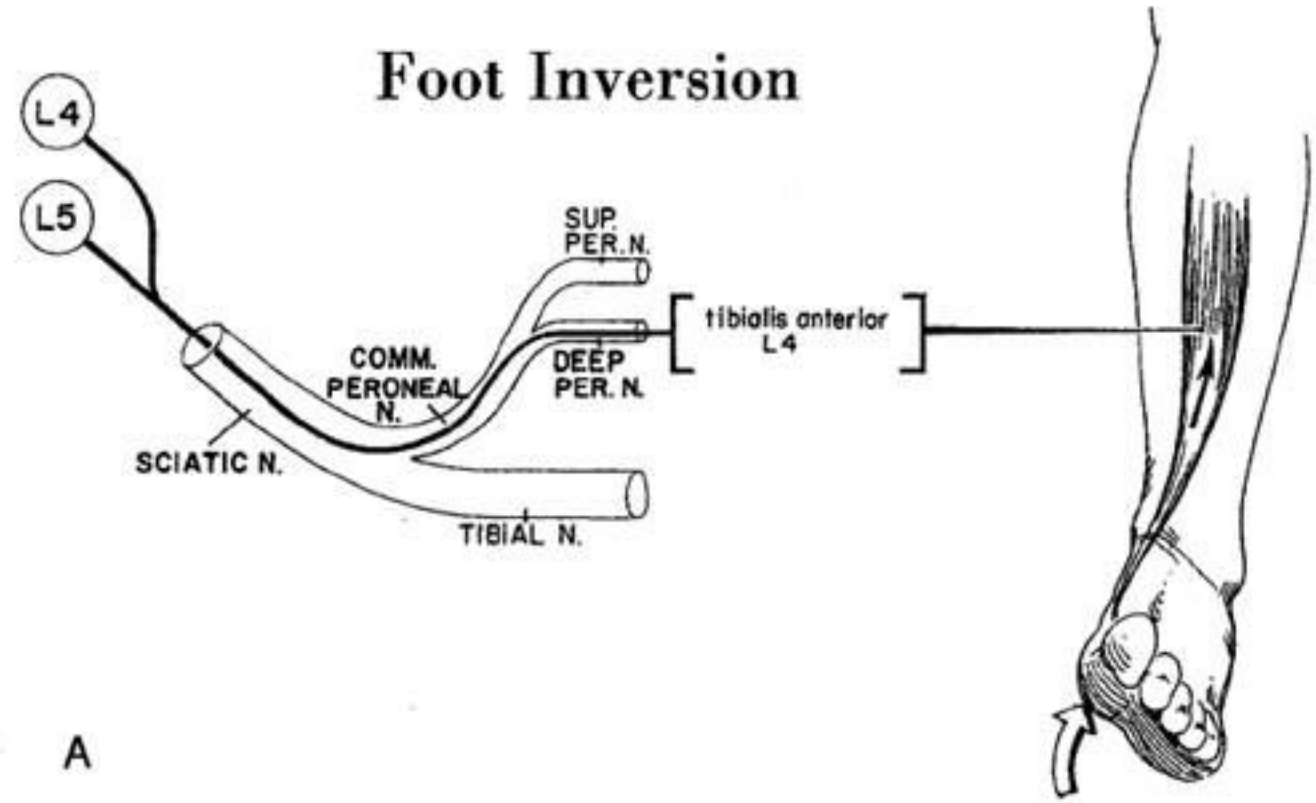

FIG. 2–11A. L4, 5 – Foot inversion.

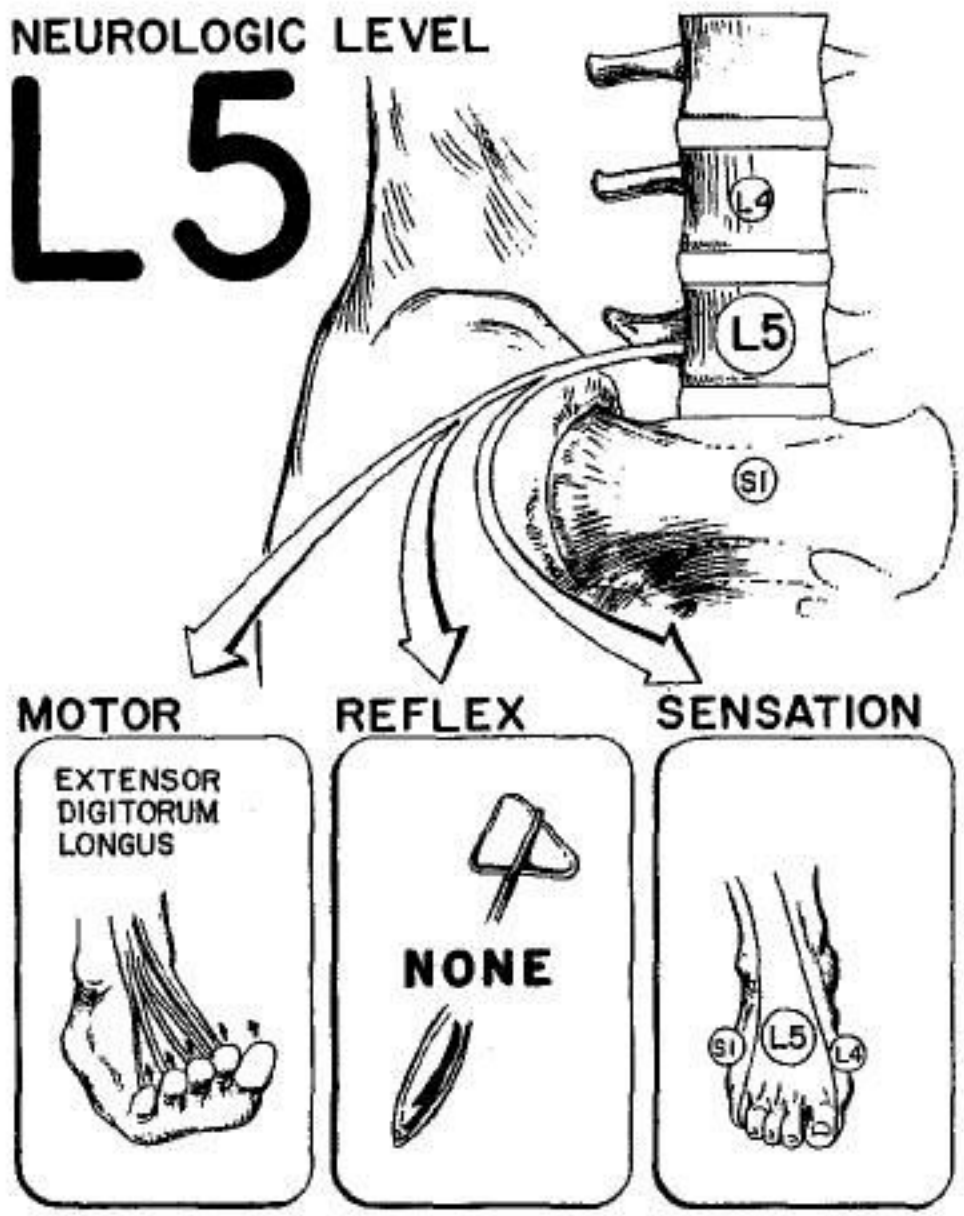

FIG. 2–15. Neurologic level L5.

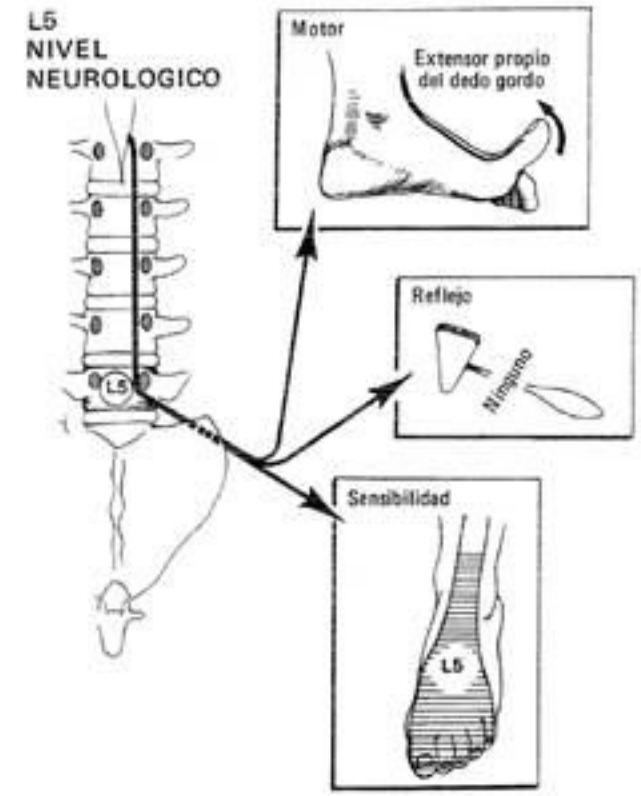

Fig. 9–31. Nivel neurológico L5.

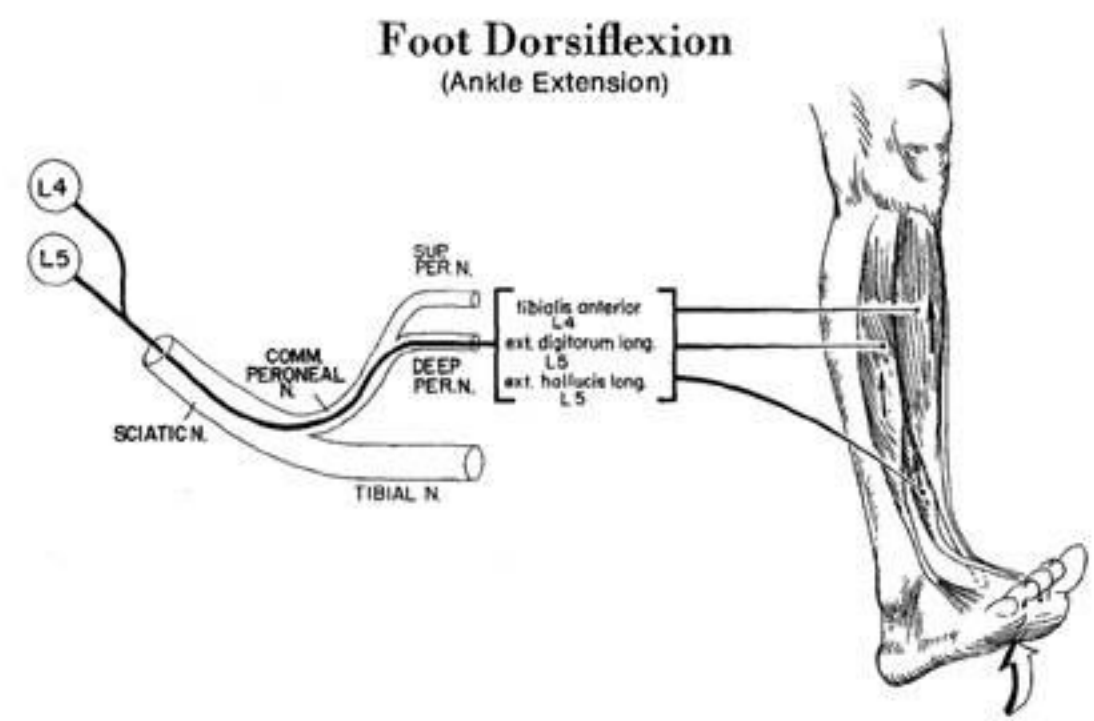

FIG. 2–16. L4, 5—Foot dorsiflexion (ankle extension).

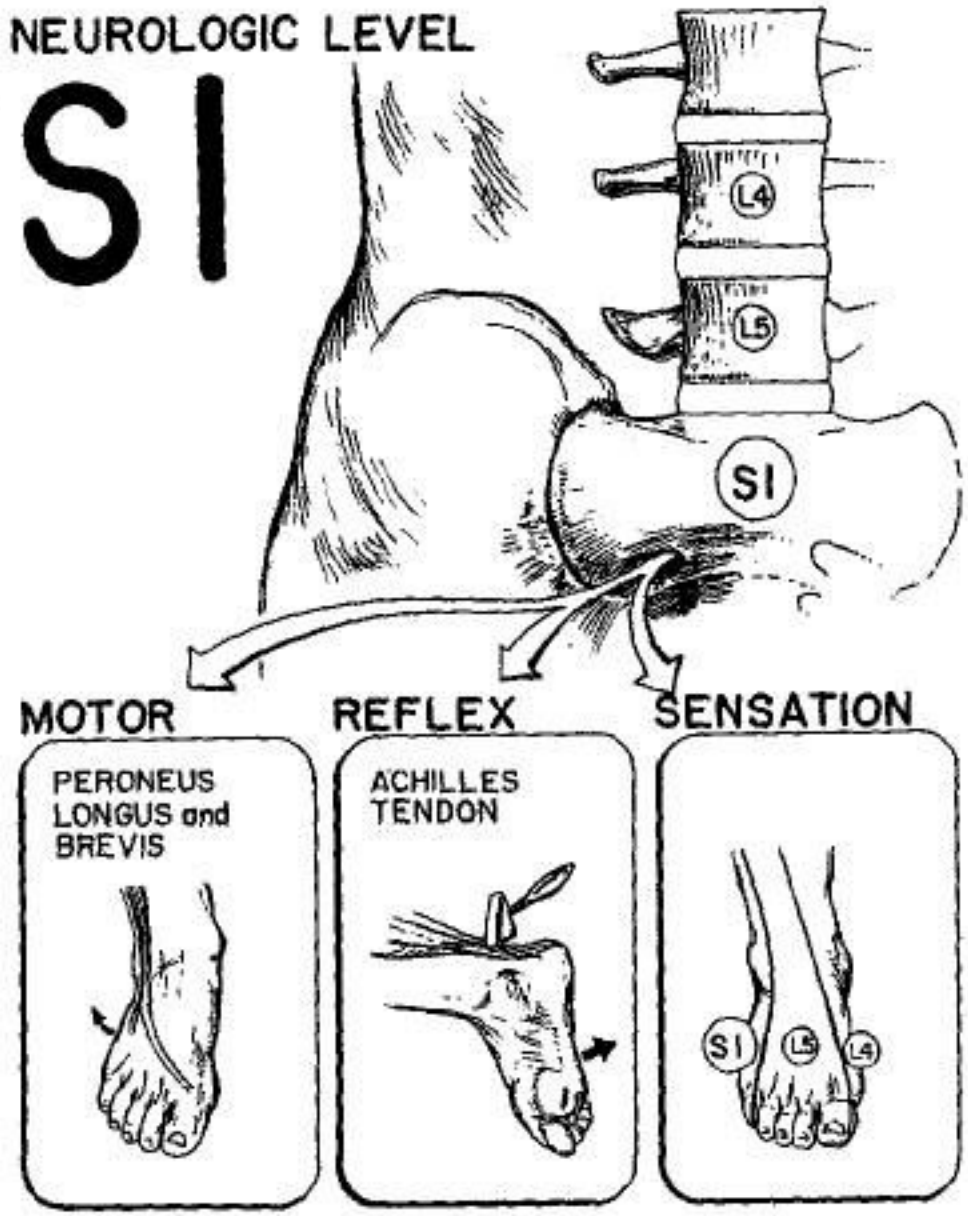

FIG. 2–22. Neurologic level S1.

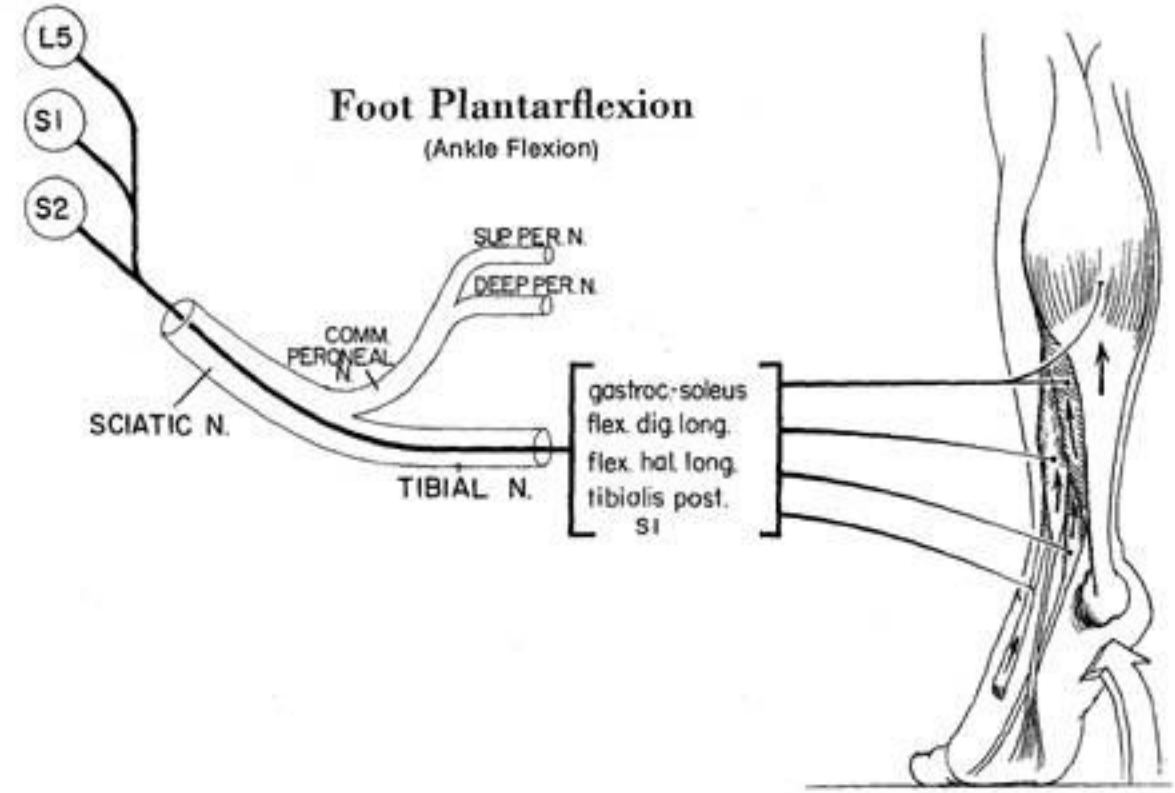

FIG. 2–25. L5, S1, 2 – Foot plantarflexion (ankle flexion).

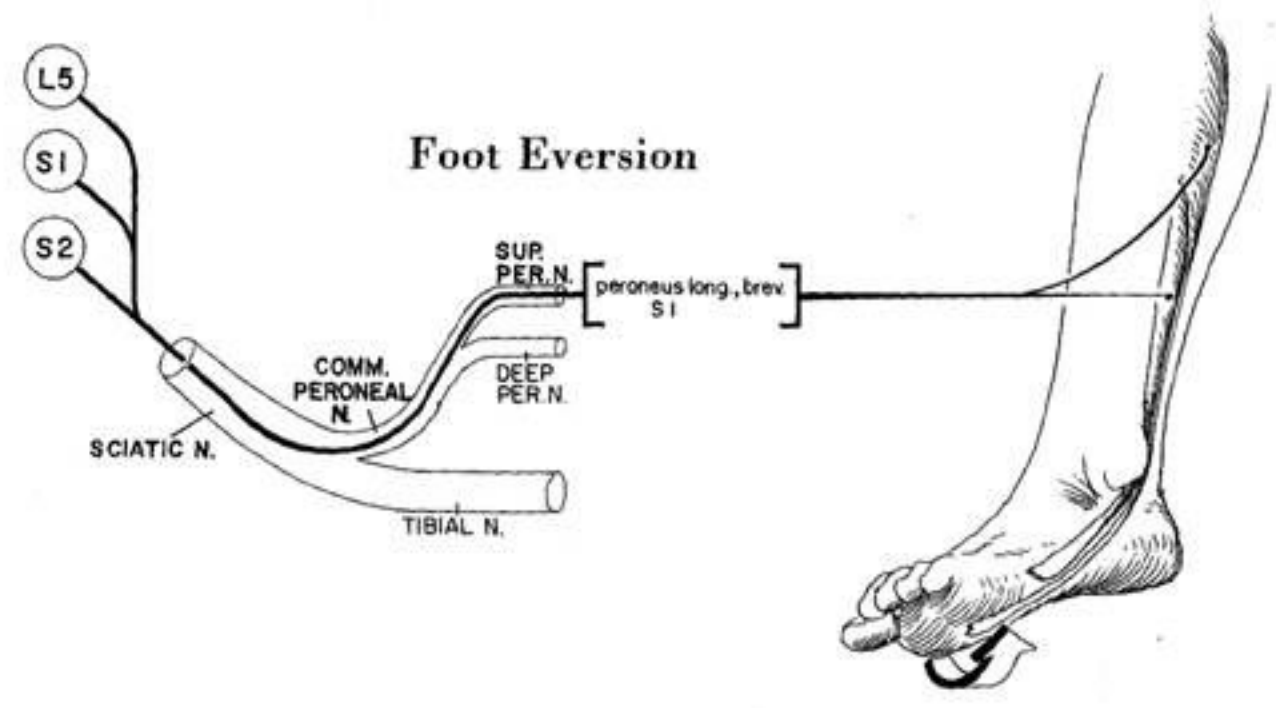

FIG. 2–23. S1 – Foot eversion.

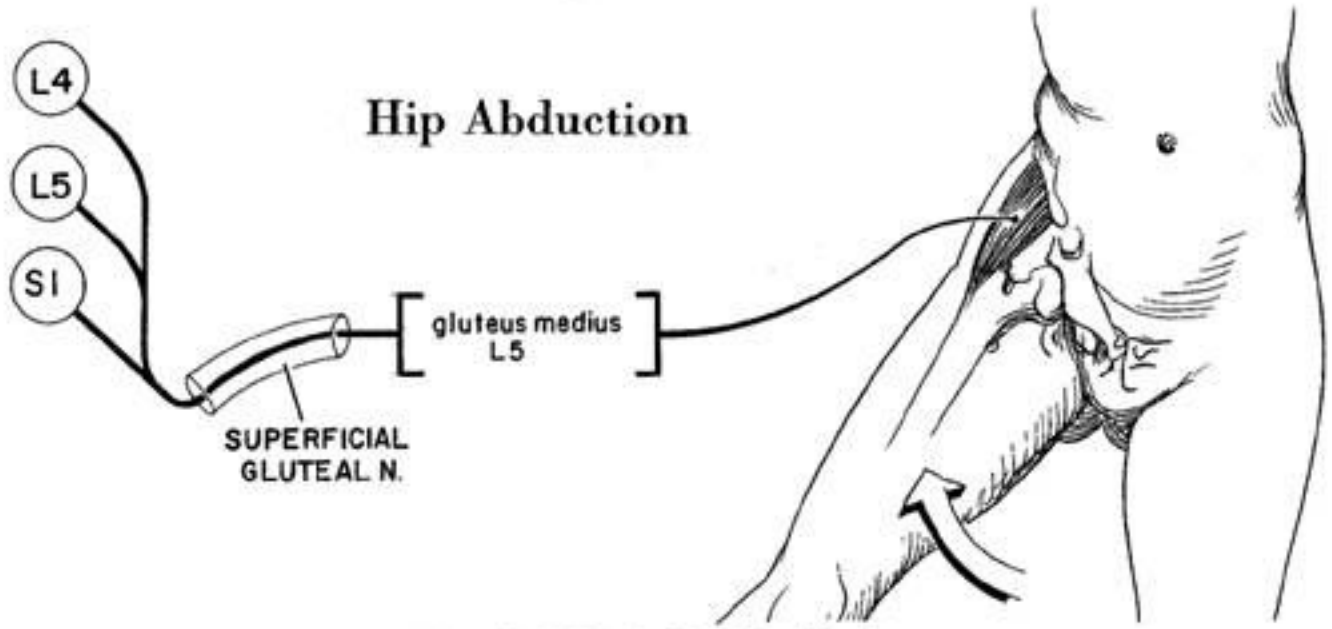

FIG. 2-19. L4, 5, S1—Hip abduction.

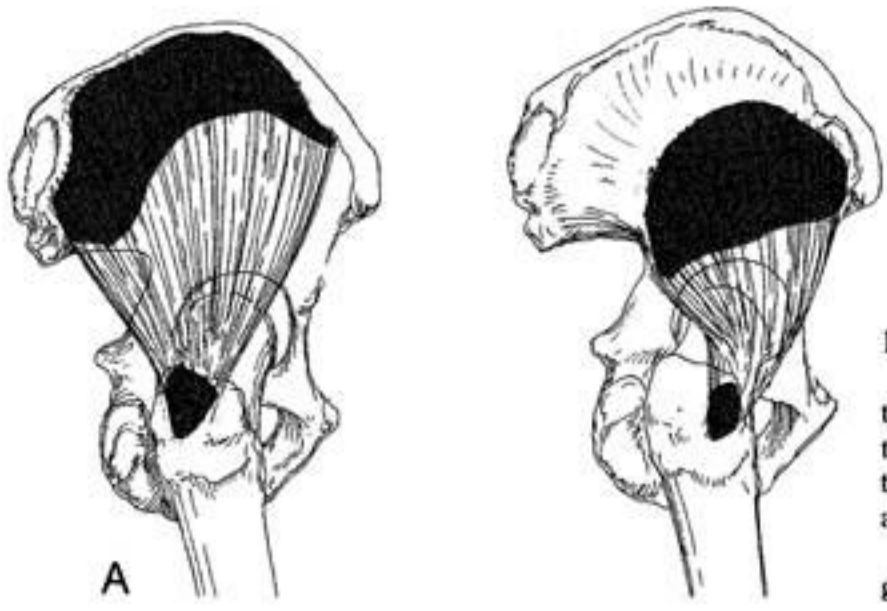

FIG. 2-20A. *Gluteus medius.*
Origin: Outer surface of ilium between iliac crest and posterior gluteal line above to the anterior gluteal line below, as well as the gluteal aponeurosis.
Insertion: Lateral surface of greater trochanter.

FIG. 2-20B. Muscle test for the gluteus medius muscle.

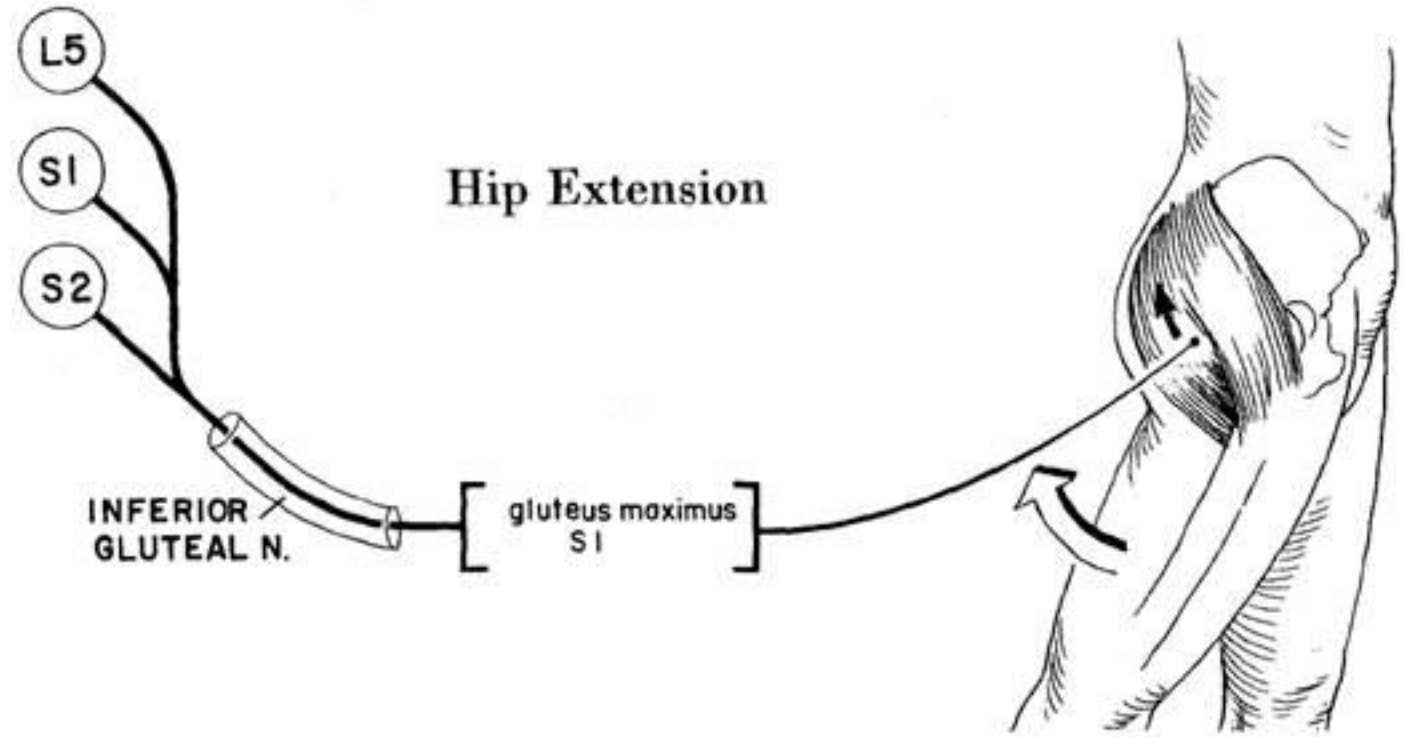

FIG. 2–27. S1 – Hip extension.

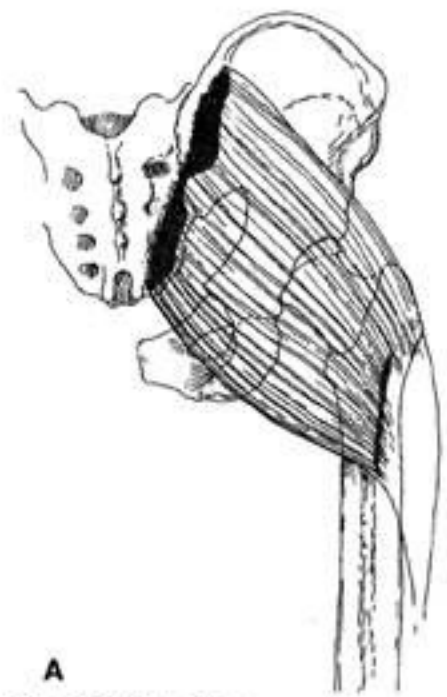

FIG. 2–28A. *Gluteus maximus.*

Origin: Posterior gluteal line and lateral lip of iliac crest, posterior surface of sacrum and coccyx.

Insertion: Iliotibial band of fascia lata, gluteal tuberosity of femur.

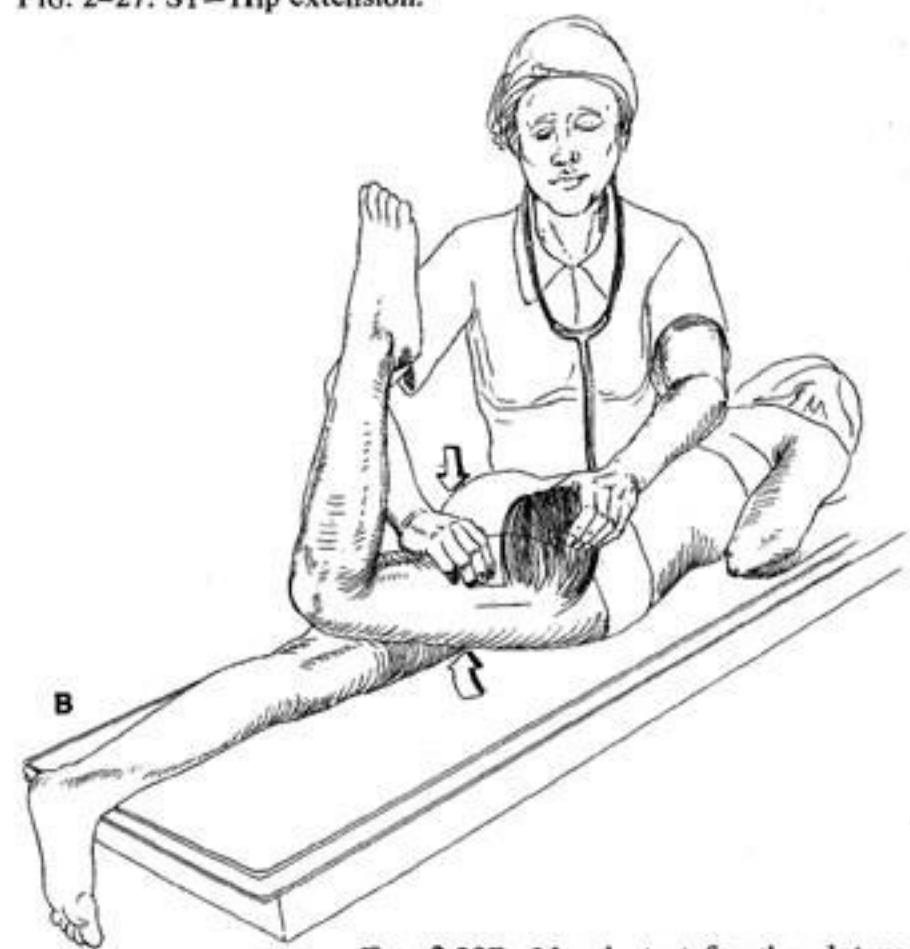

FIG. 2-28B. Muscle test for the gluteus maximus.

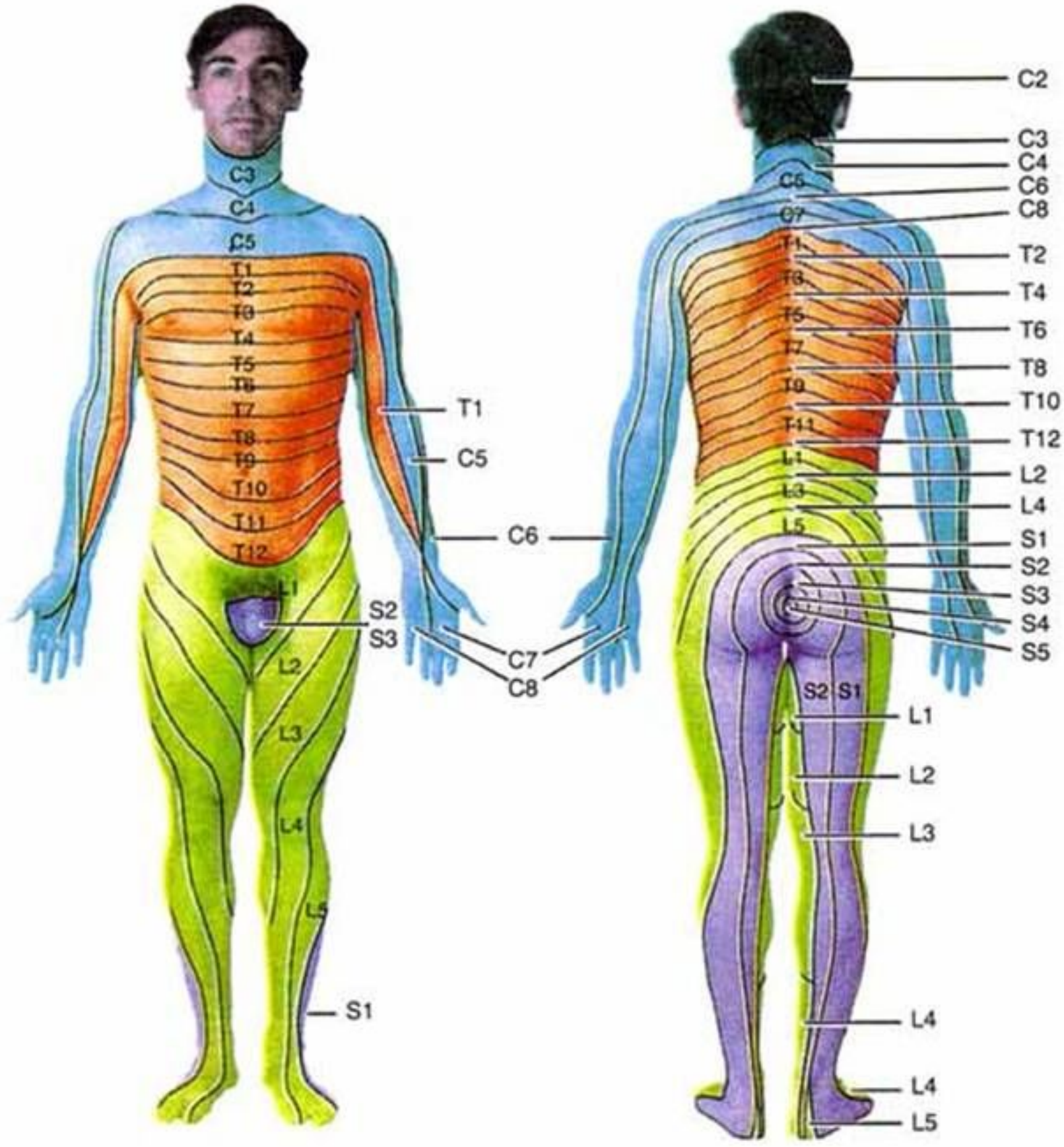
C3
C4
C5
T1
T2
T3
T4
T5
T6
T7
T8
T9
T10
T11
T12
L1
L2
L3
L4
L5
S1
S2
S3
T1
C5
C6
C7
C8
C2
C3
C4
C5
C6
C7
C8
T1
T2
T3
T4
T5
T6
T7
T8
T9
T10
T11
T12
L1
L2
L3
L4
L5
S1
S2
S3
S4
S5
S2
S1
L1
L2
L3
L4
L4
L5

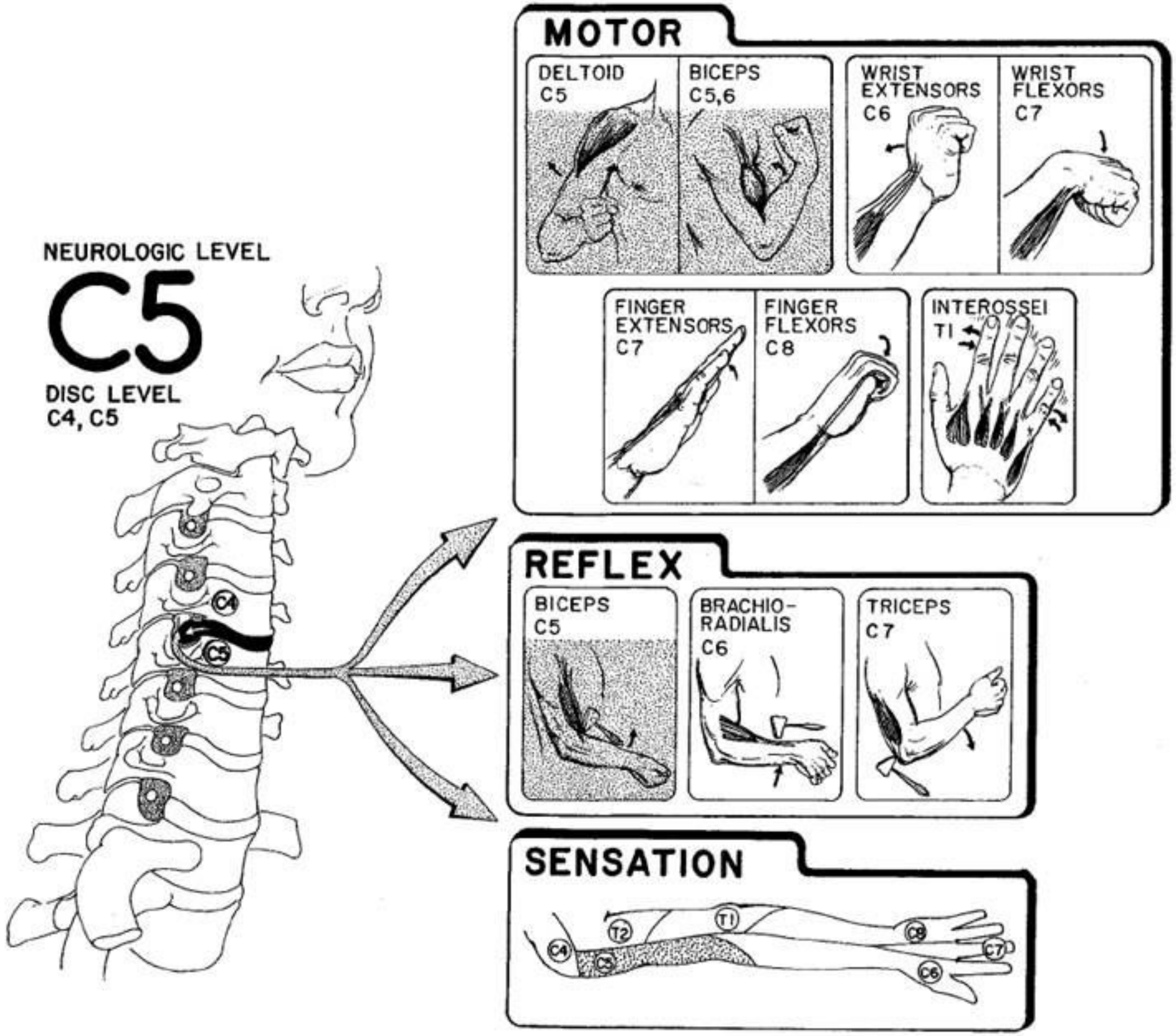

FIG. 1–39. A herniated disc between vertebrae C4 and C5 involves the C5 nerve root.

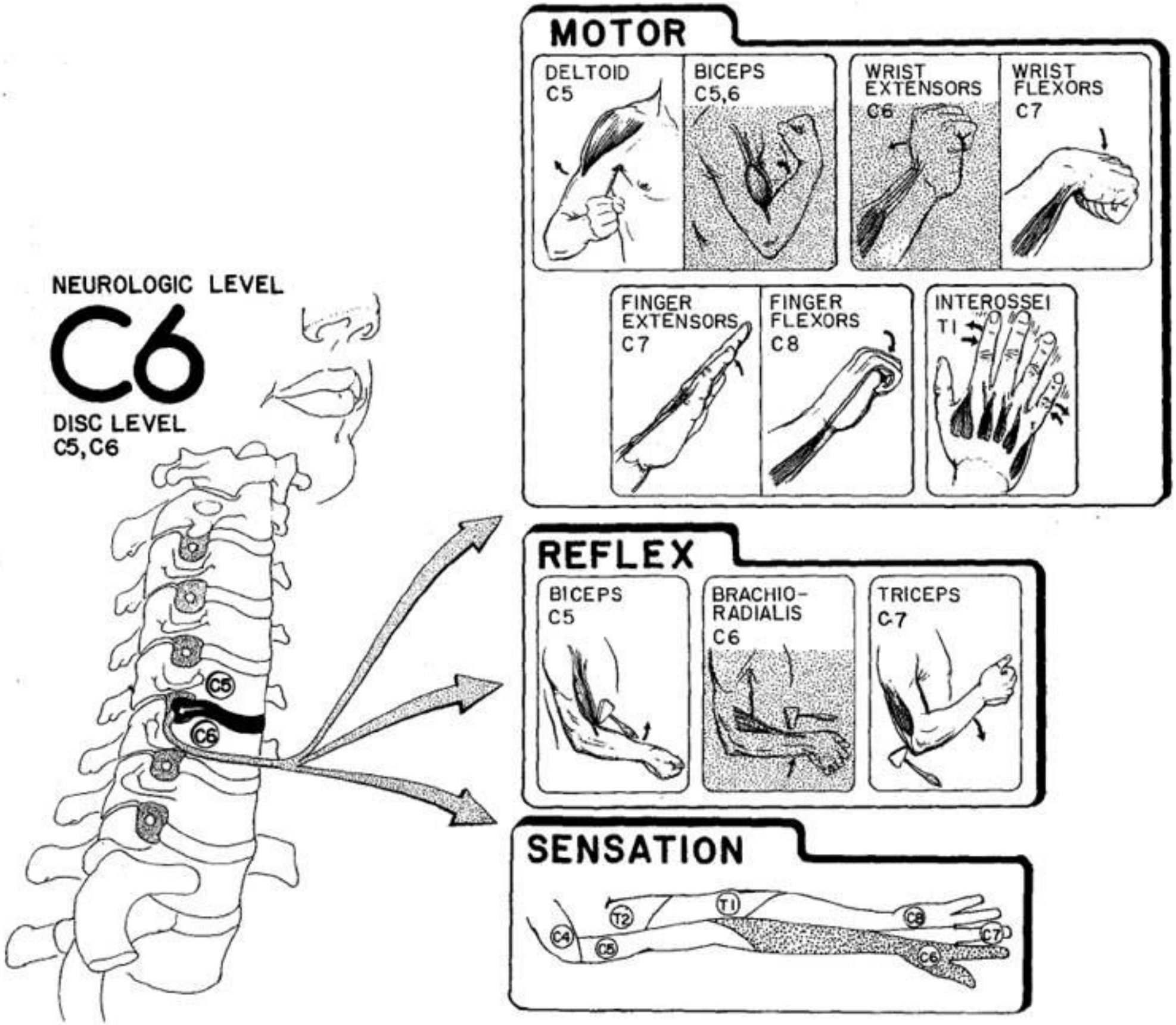

FIG. 1–40. A herniated disc between vertebrae C5 and C6 involves the C6 nerve root. This is the most common level of disc herniation in the cervical spine.

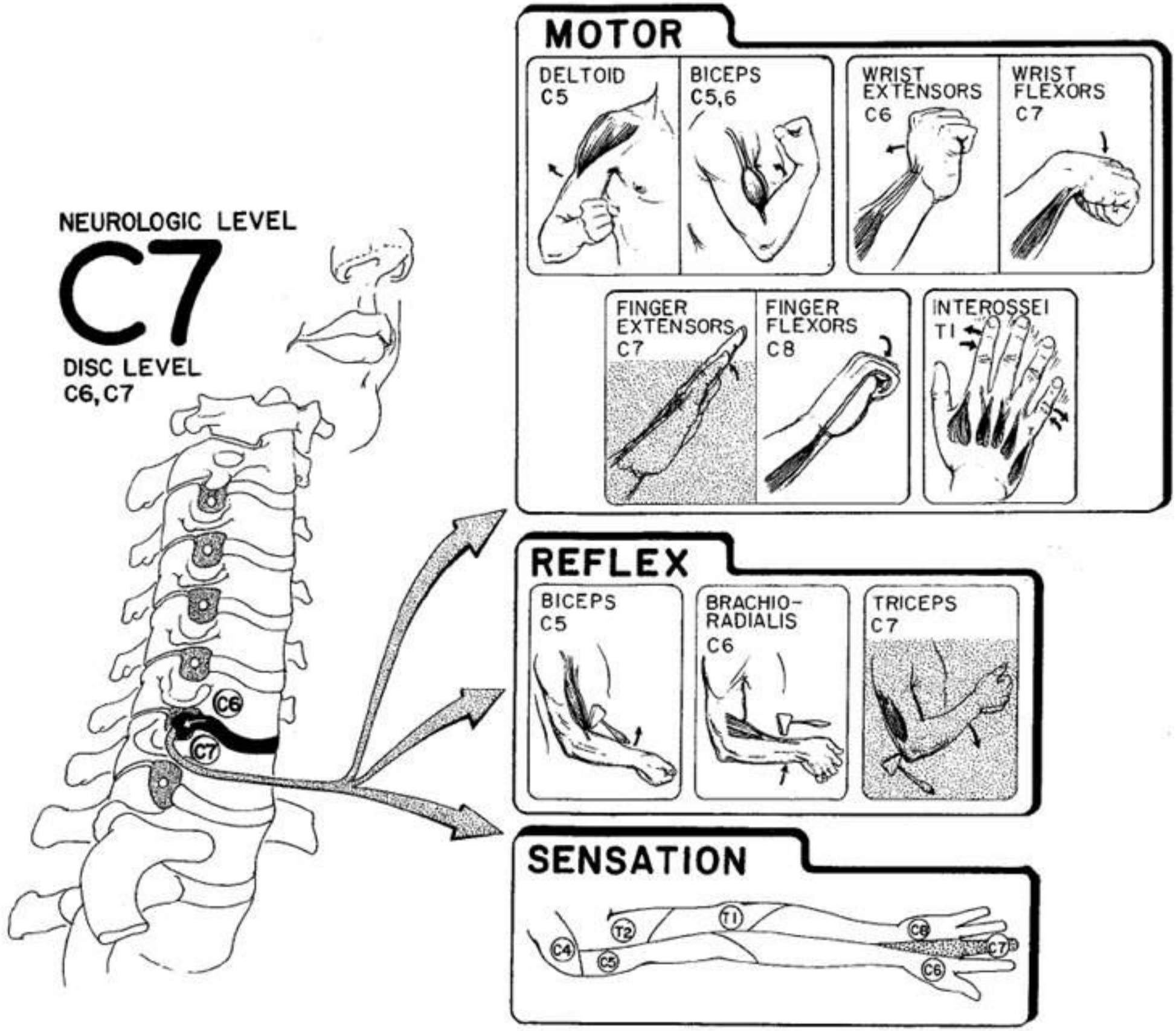

FIG. 1–41. A herniated disc between vertebrae C6 and C7 involves the C7 nerve root.

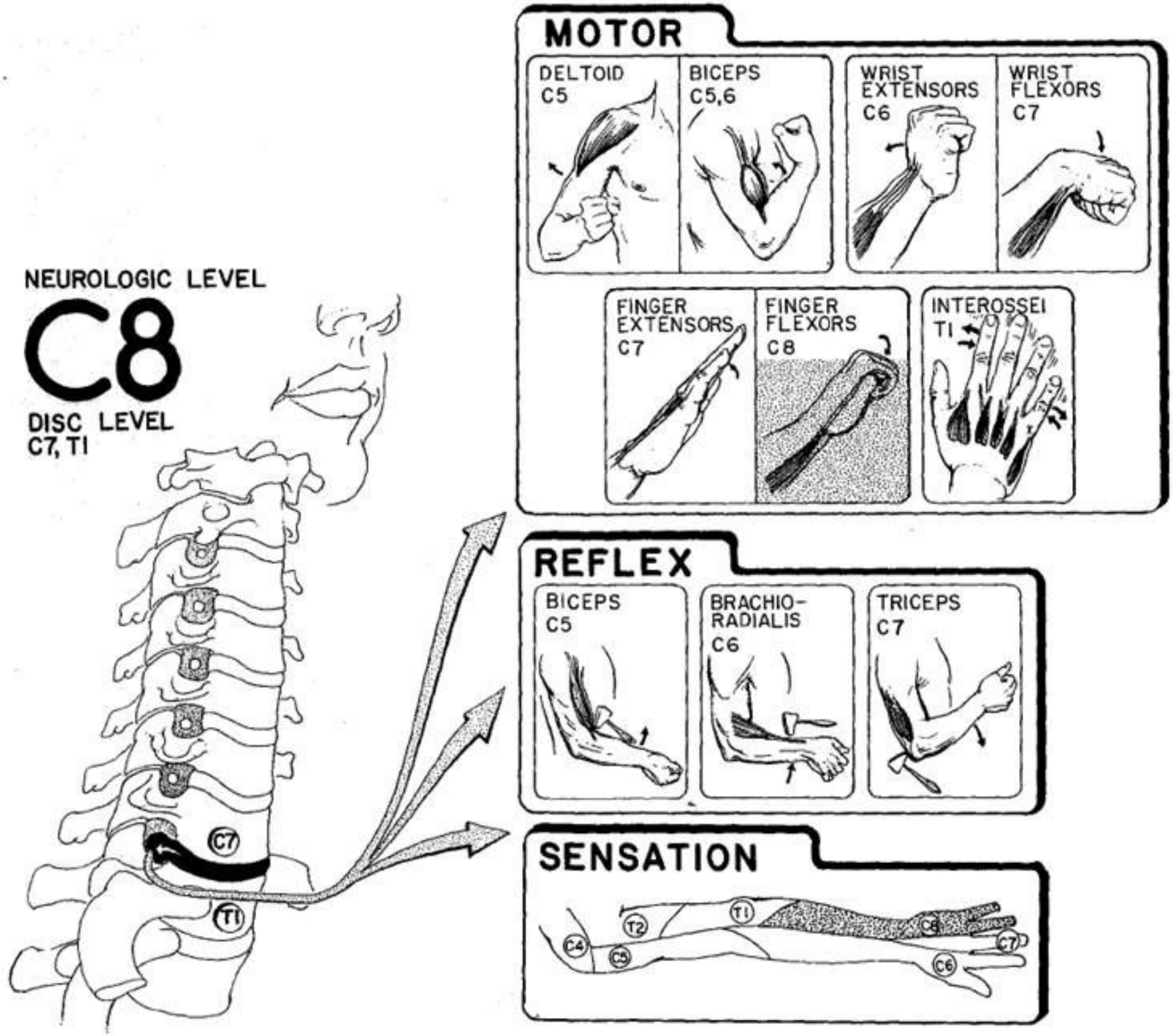

FIG. 1–42. A herniated disc between vertebrae C7 and T1 involves the C8 nerve root.

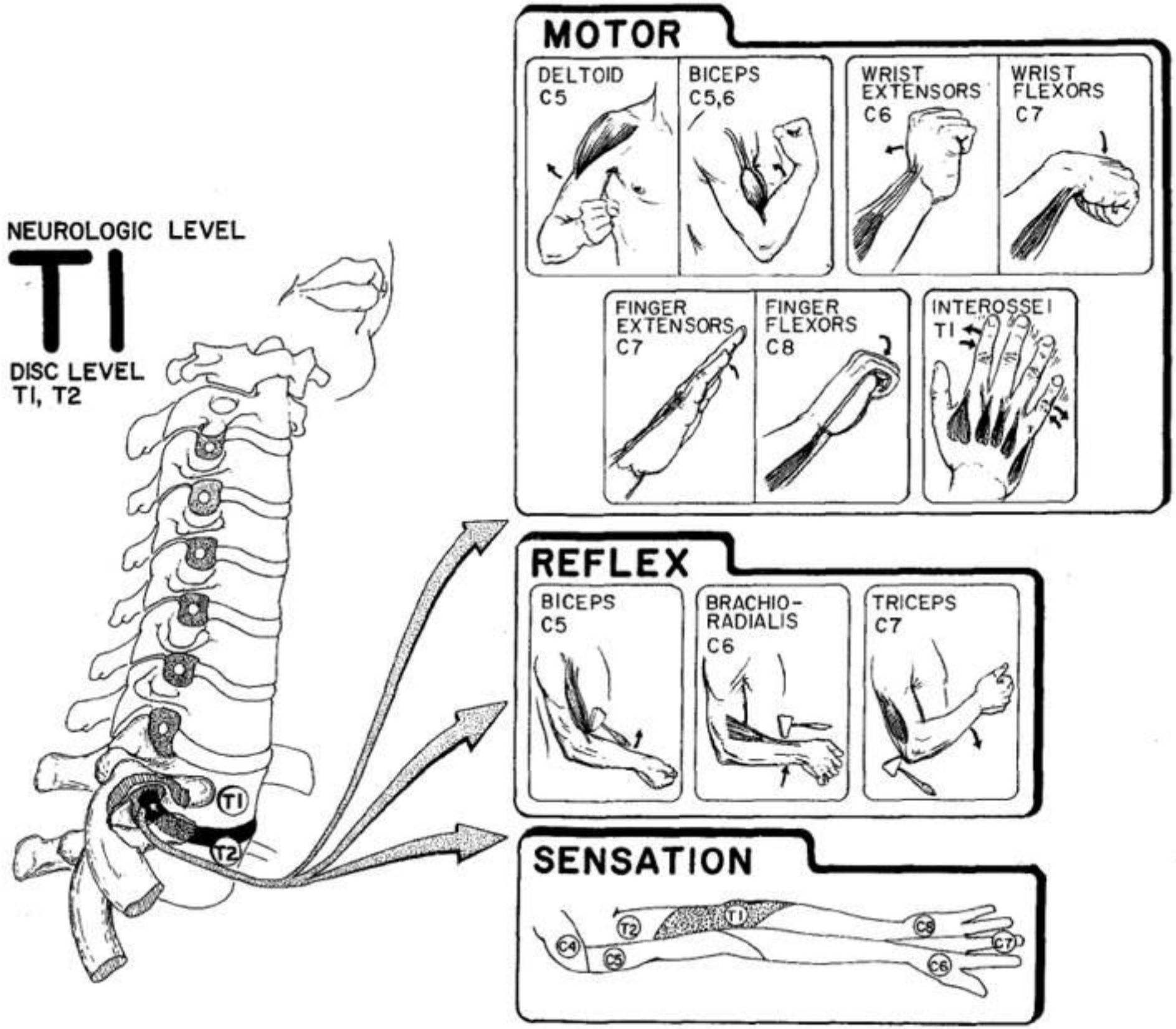

FIG. 1–43. A herniated disc between vertebrae T1 and T2 involves the T1 nerve root. A herniated disc in this area is unusual.

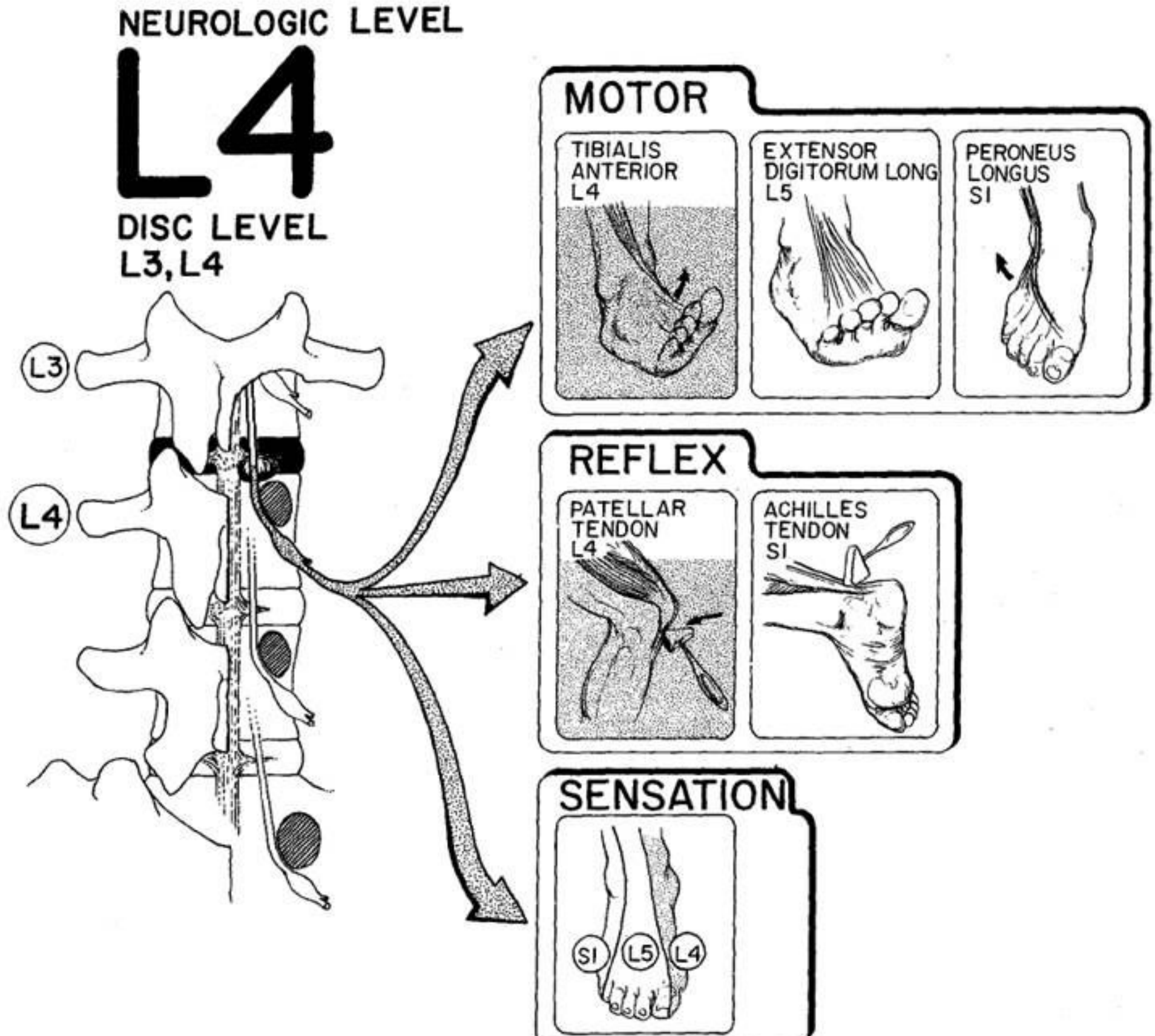

FIG. 2-35. A herniated disc between vertebrae L3 and L4 involves the L4 nerve root.

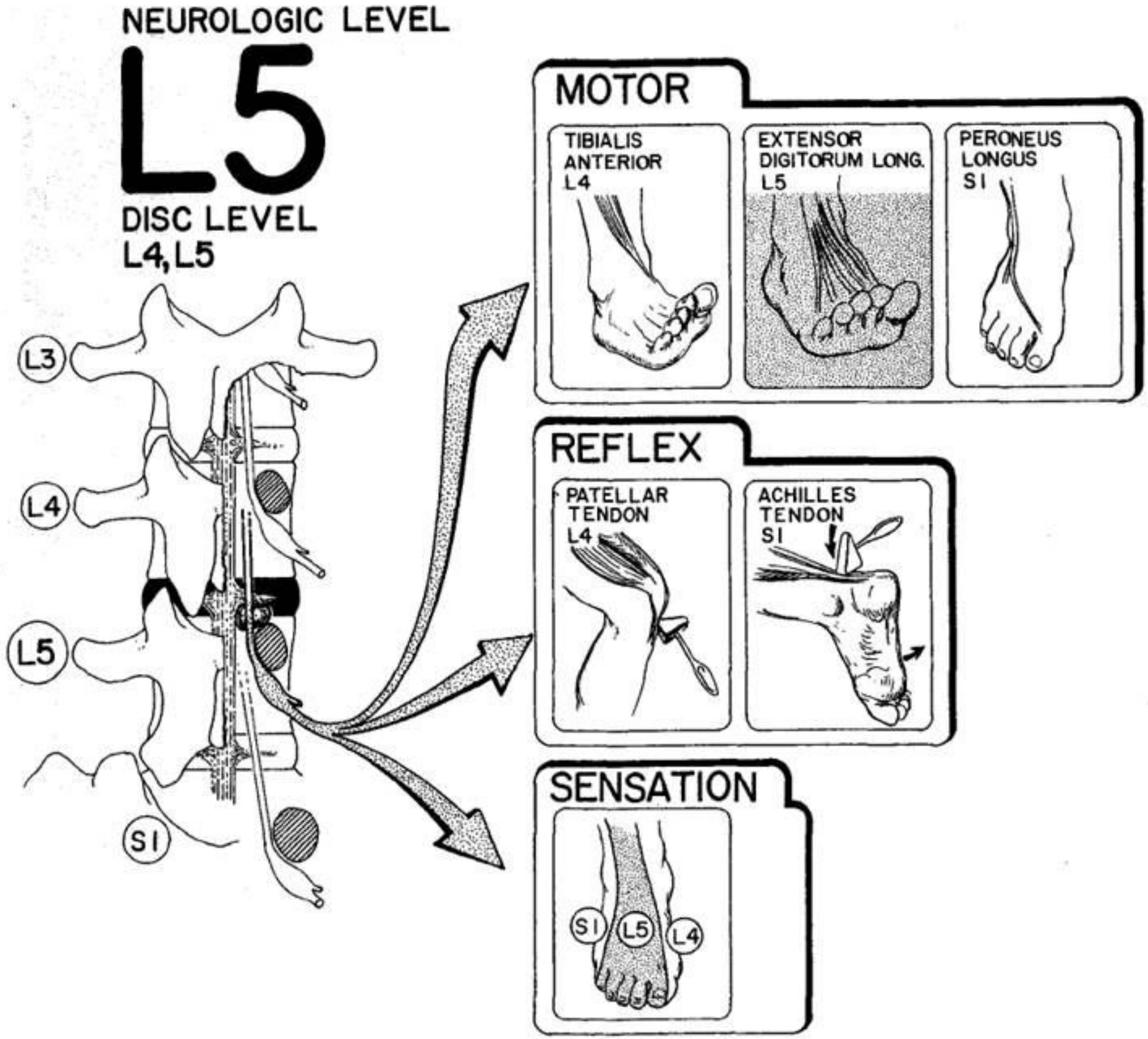

FIG. 2–36. A herniated disc between vertebrae L4 and L5 involves the L5 nerve root. This is the second most common level of disc herniation in the lumbar spine.

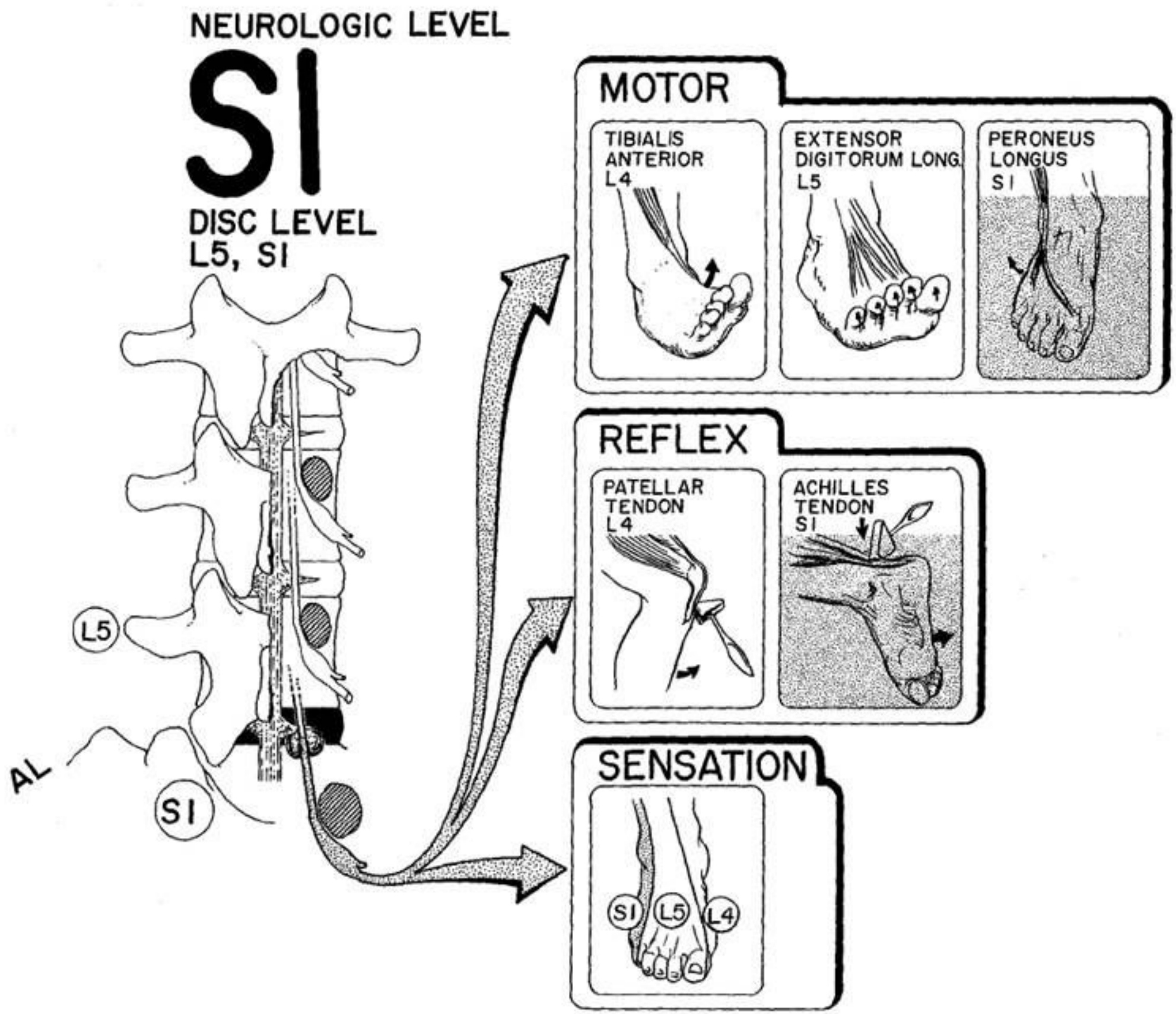

FIG. 2–37. A herniated disc between vertebrae L5 and S1 involves the S1 nerve root. This is the most common level of disc herniation in the lumbar spine.

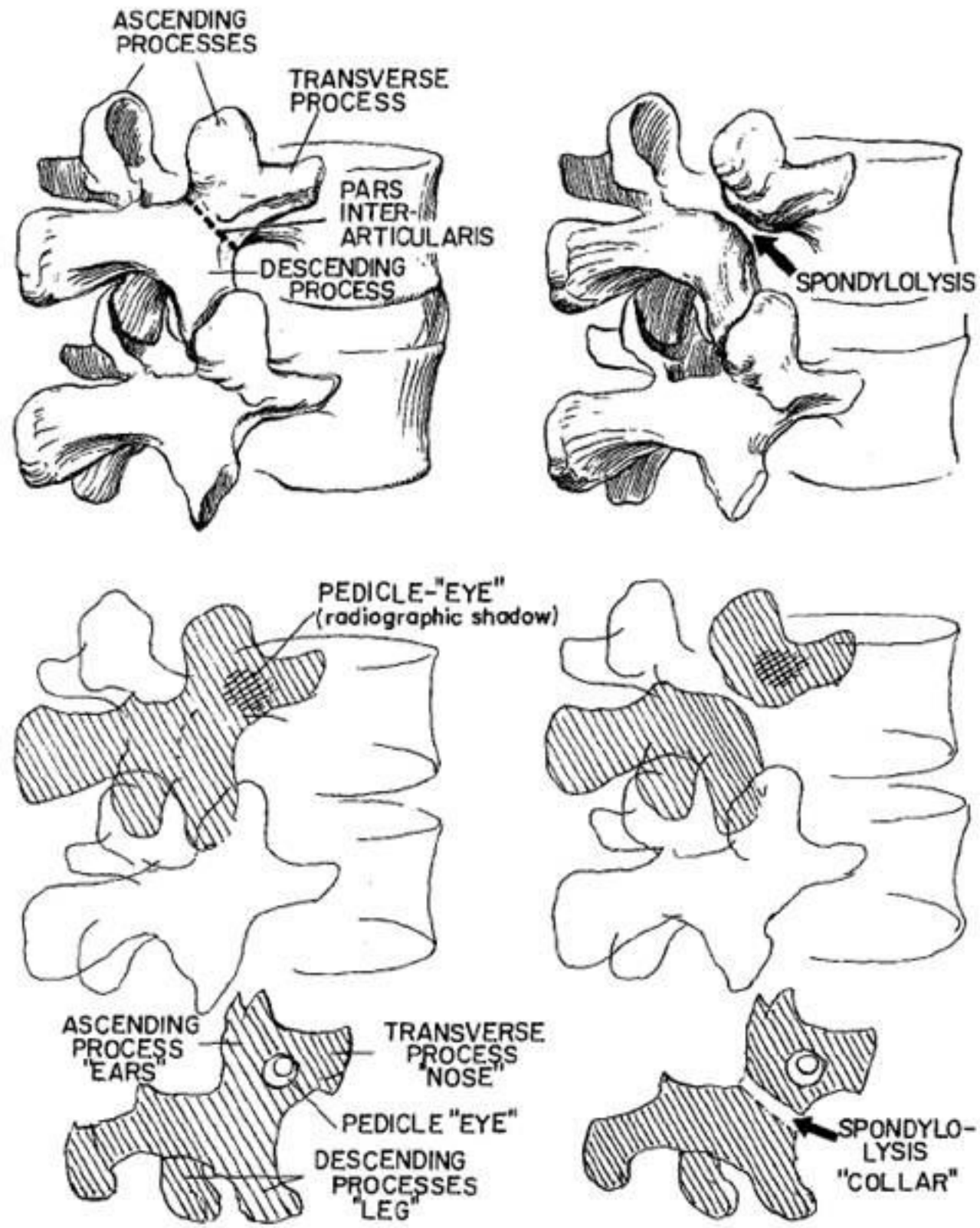

FIG. 2–39. Schematic drawing of an oblique roentgenogram of the lumbar spine, showing the characteristic "scotty dog" look of its posterior elements. Note that the defect in the pars interarticularis appears to be a collar around the dog's neck.

MUSCLE	NEUROLOGIC LEVEL*		NERVE
Hip flexors	L-1,2,3		
Hip adductors	L-2,3,4		Obturator nerve
Quadriceps	L-2,3,4		Femoral nerve
Tib. anterior	L-4,5		Deep peroneal nerve
Tib. posterior	L-4,5		Post. tibial nerve
Glut. medius	L-4,<u>5</u>	S-1	Superior gluteal nerve
Med. hamstrings	L-4,<u>5</u>	S-1	Sciatic nerve, tibial portion
Ex. Dig. longus	L-<u>5</u>	S-1	Deep peroneal nerve
Ex. Hal. longus	L-<u>5</u>	S-1	Deep peroneal nerve
Peronei	L-5	S-<u>1</u>,2	Superficial peroneal nerve
Calf	L-5	S-<u>1</u>,2	Tibial nerve
Lat. hamstring	L-5	S-<u>1</u>,2	Sciatic nerve, tibial portion
Glut. maximus	L-5	S-<u>1</u>,2	Inferior gluteal nerve
Flex. Hal. Long.	S-<u>1</u>,2		Tibial nerve
Flex. Dig. Long.	S-1,2		Tibial nerve
Toe intrinsics	S-2,3		Lat. and Med. plantar nerves
Perineum	S-2,3,4		

* According to Sharrard
<u>__</u> Predominant neurologic level

ESCALA DE LA FUERZA MUSCULAR

0: NO TIENE CONTRACCION, PARALISIS MUSCULAR

1. CONTRACCION FUERTE DEL MUSCULO PERO NO PRODUCE MOVIMIENTO

1+: CONTRACCION FUERTE DEL MUSCULO CON UN POCO DE MOVIMIENTO

2-: TRES CUARTAS PARTES DEL MOVIMIENTOSIN GRAVEDAD Y SIN RESISTENCIA

2: MOVIMIENTO COMPLETO SIN GRAVEDAD Y SIN RESITENCIA

2+: MOVIMIENTO COMPLETO SIN GRAVEDAD Y CON RESITENCIA

3-: ¾ PARTES DEL MOVIMIENTO EN CONTRA DE LA GRAVEDAD Y SIN RESISTENCIA

3: MOVIMIENTO COMPLETO EN CONTRA DE LA GRAVEDAD Y SIN RESISTENCIA

3+: MOVIMIENTO COMPLETO EN CONTRA DE LA GRAVEDAD Y RESISTENCIA LEVE

4: MOVIMIENTO COMPLETO EN CONTRA DE LA GRAVEDAD Y RESISTENCIA MODERADA

4+: MOVIMIENTO COMPLETO EN CONTRA DE LA GRAVEDAD Y BUENA RESISTENCIA

5: MOVIMIENTO COMPLETO EN CONTRA DE LA GRAVEDAD Y RESISTENCIA FUERTE.

Table 3.2 Average Ranges of Joint Motion*

Joint	Joint motion	ROM (degrees)
Hip	Flexion	90-125
	Hyperextension	10-30
	Abduction	40-45
	Adduction	10-30
	Internal rotation	35-45
	External rotation	45-50
Knee	Flexion	120-150
Ankle	Plantarflexion	20-45
	Dorsiflexion	15-30
Shoulder	Flexion	130-180
	Hyperextension	30-80
	Abduction	170-180
	Adduction	50
	Internal rotation**	60-90
	External rotation**	70-90
	Horizontal flexion**	135
	Horizontal extension**	45
Elbow	Flexion	140-160
Radioulnar	Forearm pronation (from midposition)	80-90
	Forearm supination (from midposition)	80-90
Cervical spine	Flexion	40-60
	Hyperextension	40-75
	Lateral flexion	40-45
	Rotation	50-80
Thoracolumbar spine	Flexion	45-75
	Hyperextension	20-35
	Lateral flexion	25-35
	Rotation	30-45

*Range of motion (ROM) for movements made from anatomical position (unless otherwise noted). Averages reported in the literature vary, sometimes considerably, depending on method of measurement and population measured. Values above are representative of the ranges of reported maximum ROM.

**Movement from abducted position.

EXPLORACIÓN MOTORA

VALORACIÓN MUSCULAR.

O No contrae

1 Contracción sin movimiento.

1+ contracción muscular poco movimiento sin gravedad.

2- ¾ partes del movimiento sin gravedad.

2 Movimiento completo sin gravedad y sin resistencia.

2+ Movimiento completo sin gravedad y con resistencia o ½ del movimiento en contra de la gravedad sin resistencia.

3- ¾ partes del movimiento contra la gravedad sin resistencia.

3 Movimiento completo contra la gravedad sin resistencia.

3+ Movimiento completo contra la gravedad y leve resistencia.

4 Movimiento completo contra la gravedad y moderada resistencia.

4+ Movimiento completo contra la gravedad y buena resistencia.

5 Movimiento completo contra la gravedad y excelente resistencia.

SENSIBILIDAD SUPERFICIAL.

TACTO(Meissner: superficial, Merkel: profundo)
Dolor(terminaciones libres)
Temperatura(Krausee: Frio Ruffini:Calor)

PROFUNDO.
CONCIENTE(músculos, tendones, huesos y articulaciones)
Barestesia(presión)
Barognosia(Peso)
Palestesia(vibración)
Batiestesia(posición de las partes del cuerpo)

INCONSCIENTES.
Tono muscular y equilibrio. Ojos cerrados, parado en un solo pie y brazos estirados contar hasta 5. (1 -2 Malo, 2 – 4regular y 4 – 5 Buena).

CLASIFICACIÓN DE LA PRESIÓN ARTERIAL.
OPTIMA: menor 120/ menor 80.
NORMAL: menor 130/ menor 85
PRE HTA:120 – 139/ 80 – 89
ESTADIO I: 140 – 159/ 90 – 99
ESTADIO II: mayor 160/ mayor 100
ESTADIO III: mayor 180/ mayor 110

AMA.

Cuello: Flex:35 – 40 Ext:35 – 45 Lateral: 45. Rota: 40 – 60	Hombro: Flex: 180 Ext: 50- 60 Rot int: 90 Rot Ex: 90 Abd:180 Add:125	Codo Flex:145 Ext:0 Pron: 90 Sup: 80 – 90
Muñeca Flex:80 - 90 Ext:70 – 80 Des ulnar: 35 – 45 Des. Radial: 20 - 25	Dedos Metacarpo Flex: 85 – 105 Ext:0 , 5 – 10 Abd: 20- 30 Add: 0	Interfalangicas Proximal Flex: 110- 120 Distal Flex: 80 – 90
Tronco Dorso prueba de ott Flex Ext 30 / 32-34 /28 - 29	Lumbar prueba de schover Flex Ext 10 / 14-15 / 9 Rota: 35 – 45 Lateral: 30	Cadera Flex: 125 – 130 Ext: 15 – 20 Abd:30 Add:45 Rot int: 45 Rot Ext: 45

Rodilla Flex: 130 – 140 Ext: 0 – 10	
Tobillo Dorsiflex: 20 -25 Plantiflex: 45 – 50 Inversión: 30 – 40 Eversión: 20 - 25	